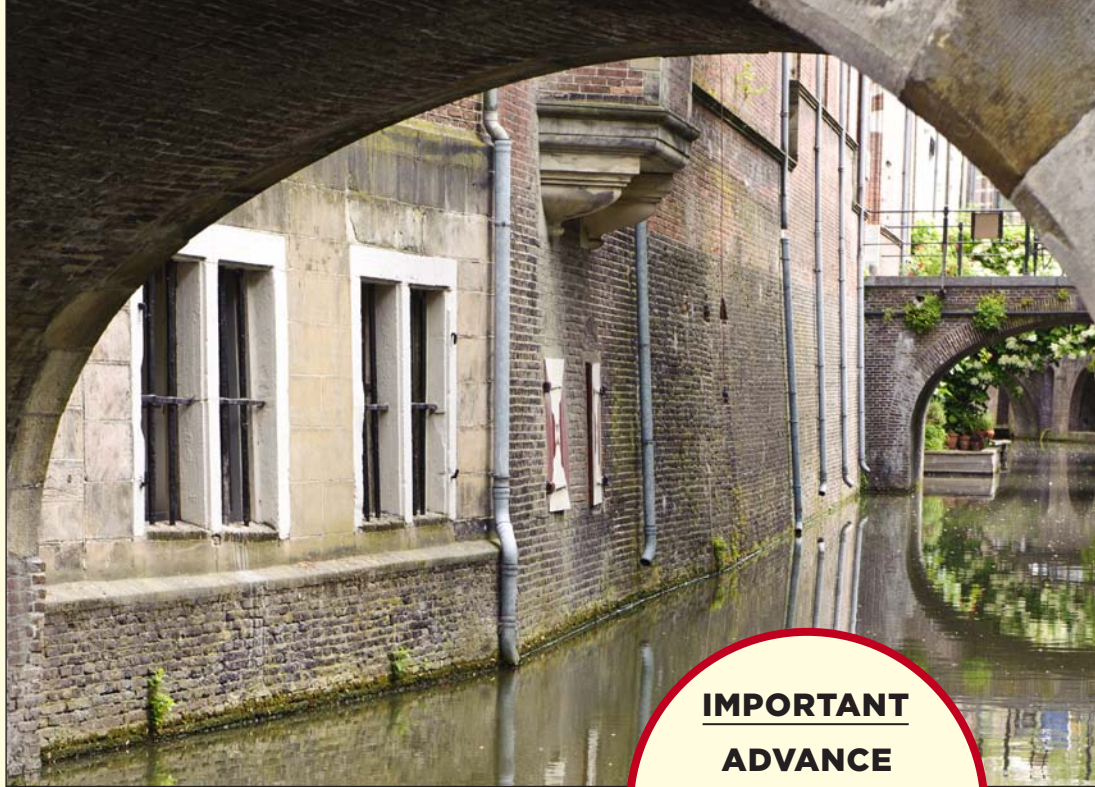




IMPORTANT
ADVANCE
REGISTRATION
DEADLINE
Friday 14 December 2012
(midnight)



WINTER MEETING

8-9 JANUARY 2013

Joint Meeting of the Pathological Society of Great Britain & Ireland
and the Dutch Pathological Society (NVVP)

Hosted by the Department of Pathology - University Medical Center - Utrecht

Venue: Academiegebouw - Domplein 29 - 3512 JE Utrecht - The Netherlands

203rd Meeting

7 JANUARY 2013 — SATELLITE MEETING



PROGRAMME ACKNOWLEDGEMENTS

This Programme is published jointly by the
Pathological Society of Great Britain & Ireland
and the Dutch Pathological Society (NVVP).

© 2013

PHOTOGRAPHS

Cover photographs are reproduced with permission.

Designed, typeset and printed in England by Byte & Type Ltd
Birmingham B29 4NN · T: 0333 666 4321 · www.bytype.co.uk

Contents

Programme Quick Reference Tables.....	4
Scientific Sessions Information.....	6
Continuing Professional Development (CPD).....	7
General Arrangements.....	7
Future Meetings.....	8
Fees and Registration.....	9
Detailed Programme	
Tuesday 8 January.....	10
Wednesday 9 January.....	17
Acknowledgements (Trade Exhibition).....	21
Poster Abstracts.....	23
Abstract Reviewers.....	53
Presenters' Index.....	54

Programme Summary

TUESDAY 8 JANUARY 2013

FOYER 08.00–09.15	Registration and Coffee
EIJKMANKAMER 09.00–18.00	Slide Seminar Competition Case Viewing: <i>Neuroendocrine Tumours</i> (<i>Competition closes at 16.30</i>) Sponsored by Philips Digital Pathology
AULA 09.00–09.10	Welcome and Introduction Prof PJ van Diest, University Medical Center Utrecht
AULA 09.10–12.30 10.40–11.10	Symposium: <i>Breast Pathology</i> Coffee and Trade Exhibition [1 st FLOOR: SENAATSZAAL & MASKERADEZAAL] Poster Viewing [BELLE VAN ZUYLEN ZAAL, ZAAL 1636 & THE FOYER]
1st FLOOR: SENAATSZAAL & MASKERADEZAAL 12.30–13.30	Lunch and Trade Exhibition
BELLE VAN ZUYLEN ZAAL, ZAAL 1636 & THE FOYER 13.30–15.00	Poster Viewing and Chairman's Rounds (<i>all categories</i>)
1st FLOOR: SENAATSZAAL & MASKERADEZAAL 15.00–15.30	Tea and Trade Exhibition
AULA 15.30–17.30	Plenary Oral Presentations
AULA 17.30–17.35	Prize Presentations: 1. Pathological Society Undergraduate Essay Competition Winner 2012 Mr A Chhabra, Liverpool 2. <i>Journal of Pathology</i> Jeremy Jass Prize for Research Excellence in Pathology in 2011 Dr M Fernanda Amary, London
AULA 17.35–18.35	Goudie Lecture: <i>MALT Lymphoma: Many Pathways Lead to NF-κB Activation</i> Prof M-Q Du, University of Cambridge
STADSKASTEEL OUDEAN RESTAURANT · UTRECHT 19.00–20.00 20.00–22.30	Brewery Tour Society Dinner

All details are subject to amendment

Visit our website for further information and updates: www.pathsoc.org

Programme Summary

WEDNESDAY 9 JANUARY 2013

FOYER 07.45–09.00	Registration and Coffee
EIJKMANKAMER 08.30–15.30	Slide Seminar Competition Case Viewing: <i>Neuroendocrine Tumours</i> Sponsored by Philips Digital Pathology
AULA 08.30–10.30	Symposium: <i>Gastrointestinal Pathology</i>
1st FLOOR: SENAATSZAAL & MASKERADEZAAL 10.30–11.00	Coffee and Trade Exhibition Poster Viewing [BELLE VAN ZUYLEN ZAAL, ZAAL 1636 & THE FOYER]
AULA 11.00–12.30	Symposium: <i>Molecular Diagnostics</i>
1st FLOOR: SENAATSZAAL & MASKERADEZAAL 12.30–14.00	Lunch and Trade Exhibition Poster Viewing [BELLE VAN ZUYLEN ZAAL, ZAAL 1636 & THE FOYER]
AULA 13.00–14.00	Meet The Experts Trainees Session: <i>Gastrointestinal Stem Cells</i> Prof JC Clevers, Hubrecht Institute, Utrecht
AULA 14.00–14.45	Slide Seminar Discussion Session: <i>Neuroendocrine Tumours</i>
AULA 14.45–15.30	Keynote Lecture: <i>Stem Cell Dynamics and Colon Cancer</i> Prof JC Clevers, Hubrecht Institute, Utrecht
15.30	Tea and Close of Meeting

All details are subject to amendment
Visit our website for further information and updates: www.pathsoc.org

Scientific Sessions Information

FREE PAPER SESSIONS

Plenary Oral Session [AULA]

Tuesday 8 January 15.30–17.30

The eight highest-ranked submitted oral abstracts will be presented. A prize for the best presentation, donated by the *Journal of Pathology* will be presented at the Society Dinner.

Poster Viewing and Chairman's Rounds [BELLE VAN ZUYLEN ZAAL, ZAAL 1636 & THE FOYER]

VIEWING

Tuesday 8 January 13.30–15.00

Wednesday 9 January 12.30–14.00

CHAIRMAN'S FORMAL POSTER ROUNDS

Tuesday 8 January 13.30–15.00

PRIZES

Poster round chairs will be circulating on Tuesday 8 January to select the winners of the Pathological Society's Sir Alastair Currie Prize and second and third poster prizes. **Winners** will be announced at the Society Dinner on Tuesday 8 January.

POSTERS – INFORMATION FOR PRESENTERS

- ◆ Poster board dimensions are: 1.0 m (high) x 0.9 m (wide). **Please do not exceed these dimensions.**
- ◆ Velcro will be provided.
- ◆ The presenting author (or another contributor) must attend the meeting and present the poster during the allocated poster rounds in order for the abstract to be published in the *Journal of Pathology On-line Supplement* (except where authors have been notified that their abstract will not be published in the *Journal*).
- ◆ Posters should be in place by 09.00 on Tuesday 8 January and **must be removed by** 15.30 on Wednesday 9 January.
- ◆ Posters need to be displayed until at least 17.30 on Tuesday 8 January as the final judging for competition will take place during the tea break.
- ◆ *Scienceposters* – the Society can offer a poster printing service via *Scienceposters*. See information on our website.

VIRTUAL SLIDE SEMINAR AND COMPETITION – Neuroendocrine Tumours

Sponsored by Philips Digital Pathology

Case Viewing (via PCs) [EIJKMANKAMER]

Competition closes: Tuesday 8 January 2013 at 16.30 hrs.

Tuesday 8 January 09.00–18.00

Wednesday 9 January 08.30–15.30

Discussion Session [AULA]

Wednesday 9 January 14.00–14.45

Prize — A case of champagne!

The winner will be announced at the Society Dinner on Tuesday 8 January, the prize being a case of champagne (which at the discretion of the winner, by tradition, is shared amongst those present at the dinner!).

General Arrangements

CONTINUING PROFESSIONAL DEVELOPMENT (CPD)

This Meeting has been approved by **The Royal College of Pathologists** for purposes of Continuing Professional Development. Credits can be accrued as follows:

Tuesday 8 January	Full day = 6 credits
Wednesday 9 January	Full day = 4 credits

The Society cannot issue certificates for less than full day attendance. Delegates should use the reflective note section of their CPD Portfolio to Self-accredit.

This Meeting has been approved by the **Dutch Society of Pathology (NVVP)** for purposes of Continuing Professional Development. Credits can be accrued as follows:

Tuesday 8 January	Full day = 7 credits
Wednesday 9 January	Full day = 5 credits

Request for Dutch Pathologists to email your **BIG** registration number to: w.vanbragt@umcutrecht.nl

SOCIETY DINNER / BREWERY TOUR [STADSKASTEEL OUDEAN RESTAURANT · UTRECHT]

Tuesday 8 January	
Brewery Tour	19.00–20.00
Dinner	20.00–22.30

[Direct Link
RESTAURANT](#)

Tickets

£25 for Undergraduates and £55 for other delegates.
Please book your ticket(s) when registering on-line.

TRADE EXHIBITION [1ST FLOOR: SENAATSZAAL & MASKERADEZAAL]

Delegates are encouraged to visit the Trade Exhibition and are requested to support the companies represented there.

PRESENTATION CHECKING AND PREVIEW [EIJKMANKAMER]

INTERNET ACCESS [EIJKMANKAMER]

Wireless access and on-site PCs will be available for delegate use. Delegates will be issued with usernames and passwords at the Registration Desk.

MESSAGES

During the Meeting, messages for delegates may be left at the following telephone number: **+44 (0)7964 024118**
There will also be a message board located beside the Registration Desk.

REFRESHMENTS [1ST FLOOR: SENAATSZAAL & MASKERADEZAAL]

Tea, coffee and lunch will be served at the times shown in the Programme.

General Arrangements / Future Meetings

BADGES

Delegates are requested to wear their badges **at all times**.

COATS AND BAGS

Secure facilities will be provided for coats and luggage.

TRAVEL, ACCOMMODATION AND VENUE INFORMATION

Please refer to the meeting website for information: www.pathsoc.org

Local Places of Interest

Please use the Direct Link to the right for information.

[Direct Link](#)
LOCAL PLACES OF INTEREST

ENQUIRIES

Enquiries before the Meeting regarding administration should be directed to:

Pathological Society of Great Britain & Ireland

2 Carlton House Terrace, London, SW1Y 5AF

Tel: +44 (0)20 7976 1260

Fax: +44 (0)20 7930 2981

Email: admin@pathsoc.org

DISCLAIMER

The Pathological Society of Great Britain & Ireland cannot be held responsible for any injury or loss sustained during the Meeting.

FUTURE MEETINGS

2013

21–25 January **Pathological Society** – Winter School for Trainees
London

18–21 June **Edinburgh Pathology 2013**
7th Joint Meeting of the British Division of the IAP and the Pathological Society

2014

31 Aug – 4 Sep **Joint Meeting with the European Society of Pathology, London**

Fees and Registration

REGISTRATION FEES			
FEES INCLUDE REFRESHMENTS AND LUNCH			
DELEGATE TYPE	FEE CATEGORIES	DAY or PART DAY <i>(after 26 Nov 2012)</i>	BREWERY TOUR and SOCIETY DINNER
Pathological Society/NVVP Members	Ordinary Members, Consultant and/or equivalent position	£ 150	£ 55
Pathological Society/NVVP Concessionary Members	Biomedical Scientists; Honorary or Senior Members; PhD Students; Post-Doctoral Fellows, Technicians and Trainees	£ 75	£ 55
Undergraduate Students *		Free	£ 25
Non-Members	Consultant and/or equivalent position	£ 225	£ 25
Non-Members Concessionary *	Biomedical Scientists; PhD Students; Post-Doctoral Fellows, Technicians and Trainees	£ 90	£ 55

ADVANCE REGISTRATION

Registration is via our on-line facility found on our website. Use the Direct Link to the right.

Advance registration will close at midnight on Friday 14 December 2012.

Thereafter delegates may only register on-site on arrival at the meeting.

Direct Link
REGISTRATION

* CONCESSIONS

Delegates from categories:

UNDERGRADUATE STUDENTS

NON-MEMBERS CONCESSIONARY

must provide an identification document as proof of their student or trainee status, including NTN's where applicable.

Proof must be by way of a statement from the Head of Department.

A template document is available on our website: www.pathsoc.org

Please e-mail documents to: julie@pathsoc.org — or fax to: +44 (0)20 7930 2981.

CANCELLATIONS

Please note that a cancellation fee of £20 will be deducted from any refund due for cancellations received in writing by Monday 3 December 2012 — no refunds will be made after this date.

DELEGATE ENROLMENT (AT THE MEETING)

The Registration Desk will be open as follows:

Tuesday 8 January – from 08.00

Wednesday 9 January – from 07.45

Detailed Programme – Tuesday 8 January 2013

Presenter = © · Abstract numbers are shown in bold and square brackets eg [S123]

- 08.00 **FOYER**
REGISTRATION AND COFFEE
- 09.00–18.00 **EIJMKAMKAMER**
SLIDE SEMINAR COMPETITION CASE VIEWING: *Neuroendocrine Tumours*
Sponsored by Philips Digital Pathology
Note: Competition closes at 16.30 today.
- 09.00–09.10 **AULA**
WELCOME AND INTRODUCTION
Prof PJ van Diest, University Medical Center Utrecht
- 09.10–12.30 **AULA**
SYMPOSIUM: *Breast Pathology*
Chair: Dr RD Liebmann, Pathological Society Meetings Secretary and Maidstone Hospital, Maidstone
Prof PJ van Diest, University Medical Center Utrecht
- 09.10–09.55 **[S1]** ***Molecular Alterations that Predict Future Malignancies: Stratifying Pre-malignant Biopsies for Progression***
© Dr TD Tlsty
University of California, San Francisco, San Francisco, CA, United States
Ductal carcinoma in situ (DCIS) is a relatively common diagnosis, yet the clinical and biologic significance of DCIS lesions is not fully understood. It appears that 5 to 10% of DCIS cases are associated with a subsequent invasive cancer within 5 years and a similar proportion has a subsequent DCIS lesion. Clinical trials and population-based studies have failed to consistently identify characteristics of women who are diagnosed with DCIS who have a high or low risk of subsequent invasive cancer. Identifying molecular marker signatures that can accurately predict subsequent DCIS and/or invasive cancer could aid in stratifying an individual's risk for subsequent tumors after a DCIS diagnosis and allow women to better tailor treatment choices to avoid unnecessary adjuvant therapy and opt for aggressive treatment when needed. Using the application of in vitro results, we have shown that DCIS samples can be stratified for subsequent tumour events (Gauthier et al, Cancer Cell 12, 479-91, 2007). We have validated these observations in a population-based cohort of women with DCIS. Thus, novel biomarkers can be developed in an in vitro system and applied to identify women at high risk of subsequent invasive tumors (Kerlikowske, et. al JNCI 102, 627-637, 2010) and these markers can be validated in a cohort of a relevant population.
- 09.55–10.40 **[S2]** ***Breast Cancer Genomics***
© Prof JS Reis-Filho
Department of Pathology, Memorial Sloan-Kettering Cancer Center, New York, United States
Breast cancer comprises a collection of different diseases that not only have distinct molecular profiles, but also risk factors, clinical presentation, prognosis and response to therapy. High throughput genomics and transcriptomics studies have revealed that oestrogen receptor (ER)-positive and -negative breast cancers are fundamentally distinct entities. The advent of massively parallel sequencing has offered unique opportunities to characterise the genomic profiles of breast cancers at an unprecedented level of detail. These studies have revealed that i) the number of highly recurrently mutated genes in breast cancer is limited and include TP53, PIK3CA, GATA3, CDH1, MAP3K1, PTEN, PIK3R1, and RUNX1, ii) there is a large number of genes that are mutated in <2% of breast cancers, iii) the constellation of genes recurrently mutated in ER-positive and ER-negative breast cancers differs, although some genes are mutated in both groups (e.g. TP53, PIK3CA), and iv) at base pair resolution, each breast cancer is unique in terms of the repertoire of mutations it harbours. The use of massively parallel sequencing has also provided evidence to demonstrate that, at diagnosis, breast cancers are composed of mosaics of clones that in addition to the founder genetic events harbour private mutations. In fact, spatial and temporal intra-tumour genetic heterogeneity occurs, given that distinct areas within a tumour have been shown to harbour distinct repertoires of mutations, and that cells harbouring specific mutations appear to be enriched in the metastatic deposit when compared to its primary tumour. In this presentation, the novel concepts emerging from massively parallel sequencing studies of breast cancer will be reviewed and their impact on our understanding of breast cancer will be discussed.

Detailed Programme – Tuesday 8 January 2013

Presenter = © · Abstract numbers are shown in bold and square brackets eg [S123]

10.40–11.10 **COFFEE AND TRADE EXHIBITION — 1st FLOOR: SENAATZAAL & MASKERADEZAAL
POSTER VIEWING — BELLE VAN ZUYLEN ZAAL, ZAAL 1636 & THE FOYER**

11.10–11.45 [S3] ***Columnar Cell Lesions of the Breast: A Practical Approach***

© Dr AHS Lee

Nottingham University Hospitals, Nottingham, United Kingdom

Interest in columnar cell lesions increased dramatically after the introduction of mammographic screening because these lesions are associated with calcification. There is a spectrum of columnar cell lesions. Columnar cell change is a lobular lesion characterised by dilated acini, with epithelial cells with bland basally located columnar nuclei, apical snouts and frequent associated calcification. Columnar cell hyperplasia is composed of similar cells, but with more layers. Flat epithelial atypia (FEA) also has dilated acini, but the epithelial cells are monotonous and evenly placed with round or oval nuclei and loss of polarity often resembling the cytology of low grade DCIS. It lacks the cribriform or micropapillary architectural features seen in ADH or low grade DCIS. Columnar cell lesions are typically oestrogen receptor and luminal cytokeratins positive and basal cytokeratins and HER2 negative. They are associated with ADH, low grade DCIS, lobular neoplasia and low grade invasive carcinomas including tubular and lobular types which share the same immunophenotype and similar genetic changes such as 16q deletions. These invasive carcinomas are in the luminal A category. Clonality has been shown between columnar cell lesions and adjacent carcinoma. These data suggest that columnar cell lesions are non-obligate precursors of low grade carcinomas. However follow up studies of FEA show low risk of recurrence. Also follow up studies of other columnar cell lesions suggest that the risk of progression is low. Columnar cell change and hyperplasia should be managed as benign lesions. After a core biopsy diagnosis of FEA the risk of associated malignancy is about 10%, much lower than for ADH-like lesions, but sufficient to recommend diagnostic excision. There are limited data on the importance of FEA at the margins of surgical specimens.

11.45–12.30 [S4] ***Context-dependent Roles for p120-catenin in Metastatic Breast Cancer***

© Dr PWB Derksen

UMC, Utrecht, Netherlands

Metastatic breast cancer cannot be treated successfully because the cellular mechanisms by which cancer cells evade current treatment regimes are not fully understood. While normal mammary cells depend on adherence junctions (AJ) for their survival, breast cancer cells can bypass this dependency upon inactivation of E-cadherin, the key component of the AJ. Despite the fact that mutational inactivation of E-cadherin is the key event leading to the development and progression of invasive lobular carcinoma (ILC), little is known about the underlying mechanisms that govern these processes. Using mouse models of human ILC, we demonstrate that – upon E-cadherin inactivation – p120-catenin (p120) translocates to the cytosol where it regulates Rock-mediated control of anchorage-independent tumour growth and metastasis through inhibition of MRIP. Conversely, since stability of the AJ can be regulated by p120-mediated turnover of E-cadherin, we also studied the effect of p120 inactivation in a mouse model of nonmetastatic mammary carcinoma. In this setting, p120 acts as a haploinsufficient tumour suppressor, resulting in the acquisition of metastatic potential and increased tumour proliferation through hyperactivation of growth factor receptor (GFR)-induced growth and survival signals. In summary, our data indicate that p120 can act as an oncogene or tumour suppressor, depending on context and timing of junctional inactivation. Furthermore, our findings suggest that targeted intervention strategies using Rock inhibition may be applicable for the treatment of ILC, while patients suffering from metastatic p120 negative breast cancer could benefit from clinically established inhibitors of GFR signaling.

12.30–13.30 **1st FLOOR: SENAATZAAL & MASKERADEZAAL
LUNCH AND TRADE EXHIBITION
POSTER VIEWING — BELLE VAN ZUYLEN ZAAL, ZAAL 1636 & THE FOYER**

Detailed Programme – Tuesday 8 January 2013

Presenter = © · Abstract numbers are shown in bold and square brackets eg [S123]

13.30–15.00 **BELLE VAN ZUYLEN ZAAL, ZAAL 1636 & THE FOYER** **POSTER VIEWING AND CHAIRMAN'S ROUNDS**

Categories	Poster Numbers
Autopsy/Forensic	P1–P3 ¹
Breast	P4–P19 ²
Cardiovascular/Pulmonary	P20–P25 ³
Cellular/Molecular Pathology	P26–P39 ⁴
Education and Audit	P40–P46 ⁵
Endocrine	P47 ⁶
Head and Neck	P48–P52 ⁶
Gastrointestinal	P53–P77 ⁷
Hepatobiliary/Pancreas	P78–P81 ⁷
Genitourinary/Renal	P82–P86 ⁸
Gynaecological	P87–P92 ⁹
Lymphoreticular	P93–P97 ¹⁰
Neonatal/Paediatric	P98–P99 ¹¹
Neuropathology/Ophthalmic	P100–P106 ¹²
Osteoarticular/Soft Tissue	P107–P108 ¹³
Skin	P110 ¹³ (Note: P109 is withdrawn)
Technical Advances	P111–P113 ¹⁴

- Chair:
- ¹ Prof P Van der Valk, Amsterdam
 - ² Dr AHS Lee, Nottingham; Prof JS Reis-Filho, New York
 - ³ Dr A Vink, Utrecht
 - ⁴ Dr C van Neusel, Amsterdam; Prof I Tomlinson, Oxford
 - ⁵ Dr JWM Chow, London; Dr A McGregor, Leicester
 - ⁶ Prof E Bloemena, Amsterdam
 - ⁷ Prof AP de Bruine, Maastricht; Prof GJA Offerhaus, Utrecht; Prof M Pignatelli, Glasgow
 - ⁸ Prof S Fleming, Dundee; Prof R Goldschmeding, Utrecht
 - ⁹ Prof CS Herrington, Dundee; Dr A McGregor, Leicester
 - ¹⁰ Dr D de Jong, Amsterdam
 - ¹¹ Dr RR de Krijger, Delft
 - ¹² Prof JE Martin, London; Prof P Van der Valk, Amsterdam
 - ¹³ Prof AM Flanagan, London
 - ¹⁴ Dr JLG Blaauwgeers, Amsterdam; Dr RA de Weger, Utrecht

15.00–15.30 **1st FLOOR: SENAATSZAAL & MASKERADEZAAL** **TEA AND TRADE EXHIBITION**

Detailed Programme – Tuesday 8 January 2013

Presenter = © · Abstract numbers are shown in bold and square brackets eg [S123]

- 15.30–17.30 **AULA**
PLENARY ORAL PRESENTATIONS
Chair: Dr RD Liebmans, Pathological Society Meetings Secretary and Maidstone Hospital, Maidstone
Prof PA Hall, Editor-in-Chief, *Journal of Pathology* and King Faisal Specialist Hospital and
Research Center, Riyadh, Saudi Arabia
- 15.30–15.45 **[PL1]** ***High-Risk Human Papillomavirus Testing Versus Cytology in Predicting Post-Treatment Disease in Women Treated for High-Grade Cervical Disease: A Systematic Review and Meta-Analysis***
M Kocken¹; © MH Uijterwaal¹; AL De Vries¹; J Berkhof¹; JCF Ket¹; TJM Helmerhorst²;
CJL Meijer¹
¹VU Medical Center, Amsterdam, Netherlands; ²Erasmus Medical Center, Rotterdam, Netherlands
Objective: Currently, women treated for high-grade cervical intraepithelial neoplasia (CIN 2/3) are followed-up by cytology to monitor them for post-treatment disease. This systematic review and meta-analysis determines test performance of testing for high-risk human papillomavirus (hrHPV), cytology and co-testing (combined hrHPV testing and cytology) in predicting high-grade post-treatment disease (CIN2+).
Methods: Studies that compared at least two of three post-treatment surveillance methods, and were published between January 2003 and May 2011, were identified through a bibliographic database search. Identification of relevant studies was conducted independently by two reviewers with a multi-step process. The reference standard used to diagnose post-treatment disease was histologically confirmed CIN2+. Sensitivity, specificity, diagnostic odds ratios and relative sensitivity and specificity were calculated for each study. Estimates were reported with 95% confidence intervals (95%CI).
Results: Out of 2410 potentially relevant citations, 8 publications, incorporating 1513 treated women, were included. Pooled sensitivities were 0.79 (95%CI 0.72–0.85) for cytology, 0.92 (0.87–0.96) for hrHPV testing, and 0.95 (0.91–0.98) for co-testing. HrHPV testing was more sensitive than cytology to predict post-treatment CIN2+ (relative sensitivity 1.15; 95%CI 1.06–1.25). Pooled specificities were 0.81 (95%CI 0.74–0.86) for cytology, 0.76 (0.67–0.84) for hrHPV testing and 0.67 (0.60–0.74) for co-testing. HrHPV testing and cytology had a similar specificity (relative specificity 0.95, 95%CI 0.88–1.02).
Conclusions: This review indicates that the hrHPV test should be included in post-treatment testing 6 months after treatment, because hrHPV testing has a higher sensitivity than cytology in detecting high-grade post-treatment disease and has a similar specificity.
- 15.45–16.00 **[PL2]** ***Detection of HPV Infection in Head and Neck Squamous Cell Carcinoma: A Practical Proposal***
Dreyer, J¹; Hauck, F²; de Oliveira e Silva, M³; Barros, MHM¹; © Niedobitek, G⁴
¹Unfallkrankenhaus Berlin, Berlin, Germany; ²Sana Klinikum Lichtenberg, Berlin, Germany; ³Instituto Nacional de Câncer, Rio de Janeiro, Brazil; ⁴Unfallkrankenhaus Berlin/Sana Klinikum Lichtenberg, Berlin, Germany
Detecting HPV infection in head and neck squamous cell carcinoma (HNSCC) is becoming clinically relevant but there is no agreement about the most appropriate methodology.
We have studied 64 oropharyngeal carcinomas using p16 immunohistochemistry, HPV DNA in situ hybridisation (ISH) and HPV DNA PCR followed by pyrosequencing. We have also evaluated a new assay, RNAscope, designed to detect HPV E6/E7 RNA transcripts.
Using a threshold of 75% labelled tumour cells, 21 cases (32.8%) were p16-positive. Of these, 19 cases yielded a positive result with at least one of the three HPV detection assays. 16 cases were positive by HPV DNA ISH and 18 cases were positive using the E6/E7 RNAscope assay. By PCR and pyrosequencing, HPV16 was detected in 15 cases, while one case each harboured HPV33, 35, and 56. All p16-negative cases were negative using these assays. Using RNase digestion experiments, we show that the signal obtained with the RNAscope HPV E6/E7 RNA ISH assay is RNase sensitive but is not completely abolished suggesting cross hybridisation to viral DNA.
We conclude that p16 expression is a useful surrogate marker for HPV infection in HNSCC with a high negative predictive value and that p16-positive cases should be further evaluated for HPV infection, preferably by PCR followed by type determination. We also show that the RNAscope HPV E6/E7 assay is not suitable for the reliable discrimination between E6/E7 RNA transcripts and viral DNA.
- 16.00–16.15 **[PL3]** ***CD44 and OTP are Strong Prognostic Markers for Pulmonary Carcinoids***
DRA Swarts¹; M Henfling¹; L van Neste²; R van Suylen³; AM Dingemans¹; WNM Dinjens⁴;
A Haesevoets¹; M Rudelius⁵; FBJ Thunnissen⁶; M Volante⁷; W van Criekinge⁸;
M van Engeland¹; FCS Ramaekers¹; © EJM Speel¹
¹Maastricht UMC, Maastricht, Netherlands; ²MDxHealth, Irvine, United States; ³Jeroen Bosch Hospital's, Hertogenbosch, Netherlands; ⁴Erasmus MC, Rotterdam, Netherlands; ⁵Technical University Munich, Munich, Germany; ⁶Free University MC, Amsterdam, Netherlands; ⁷University of Turin at San Luigi Hospital, Turin, Italy; ⁸Ghent University, Ghent, Belgium
Purpose: Pulmonary carcinoids are well-differentiated neuroendocrine tumors showing usually a favorable

prognosis. However, there is a risk for late recurrence and/or distant metastasis. Because histological classification in typical and atypical (AC) carcinoids is difficult and its reliability to predict disease outcome varies, we evaluated three genes as potential prognostic markers, i.e., OTP, CD44 and RET.

Methods: These genes were analyzed in 56 frozen carcinoids by quantitative RT-PCR. RET was further studied by methylation and mutation analysis. Immunohistochemistry for CD44 and OTP protein expression was performed on 292 carcinoids.

Results: Low mRNA expression levels of CD44 ($p=1.3e-5$) and OTP ($p=0.012$), and high levels of RET ($p=0.0025$), were strongly associated with a low 20-year survival of carcinoid patients. High RET expression was not related to promoter hypomethylation or gene mutations. A direct link between gene expression and protein levels was confirmed for CD44 and OTP, but not for RET. Within all carcinoids as well as ACs, absence of CD44 protein was significantly associated with low 20-year survival ($p=8.6e-5$ and $p=0.00015$, respectively). The absence of nuclear OTP followed by complete loss of expression was also significantly associated with unfavorable disease outcome in all carcinoids ($p=2.9e-5$). Multivariate analysis revealed that CD44 and OTP immunostaining combined with histopathology is the optimal indicator for patient outcome.

Conclusions: Our study indicates that CD44 and OTP are strong indicators of poor outcome. We therefore argue for implementation of these markers in routine diagnostics in addition to histopathology to improve subclassification of pulmonary carcinoids into prognostically relevant categories.

16.15–16.30 [PL4] **Neoadjuvant Chemotherapy Induces Changes in Expression of Breast Cancer Resistance Protein that Predict Disease Free Survival in Breast Cancer**

B Kim¹; BJ Williams²; H Fatayer³; AM Hanby²; K Horgan³; JL Thorne⁴; EMA Valleley⁴; ET Verghese⁴; © TA Hughes⁴

¹Leeds Institute of Molecular Medicine, Leeds, United Kingdom; ²Department of Histopathology, St. James's University Hospital, Leeds, United Kingdom; ³Department of Breast Surgery, Leeds General Infirmary, Leeds, United Kingdom; ⁴Leeds Institute of Molecular Medicine, St. James's University Hospital, Leeds, United Kingdom

Introduction: Three main xenobiotic efflux pumps have been implicated in modulating breast cancer response to chemotherapy. These are Pgp (P-glycoprotein, multidrug resistance protein-1), MRP1 (multidrug resistance-associated protein 1), and BCRP (breast cancer resistance protein). We aimed to investigate expression of these proteins before and after neoadjuvant chemotherapy (NAC) to determine whether levels define response to NAC or subsequent survival.

Methods: Paraffin embedded tissue was collected representing matched pairs of core (pre-NAC) and surgical specimens (post-NAC) from 45 patients with invasive ductal carcinomas (follow-up range 3-8.8 years). NAC regime consisted of anthracyclines +/- taxanes. Immunohistochemistry was performed. A computer-aided scoring protocol was developed and validated against 2 independent observers (intra-class correlation coefficient 0.83 and 0.82).

Results: Pgp and MRP1 expressions were significantly upregulated after exposure to NAC ($p=0.0024$ and $p<0.0001$). BCRP expression showed more variation in response: individual cases showed either down- (41%) or up-regulation (59%) after NAC. Pre- or post-NAC expression of Pgp, MRP1 or BCRP did not correlate with clinical response to NAC. However, expression of BCRP post-NAC, but not pre-NAC, correlated with disease free survival (DFS): significantly longer 5-year DFS was seen in patients with low expression compared to high expression (80% vs. 40%; Log rank $p=0.007$).

Conclusion: High expression of BCRP after treatment with NAC is an adverse event, and investigating mechanisms that control BCRP induction and repression may improve NAC efficacy.

16.30–16.45 [PL5] **Crypt Cell Dysplasia with Maturation in Barrett's Esophagus Shows Clonal Identity between the Crypt and Surface Cells**

© NA Wright¹; S Khan¹; SAC McDonald¹; S Galandiuk²; TA Graham³; RD Odze⁴; M Rodriguez-Justo⁵; S Zeki¹

¹Barts and the London School of Medicine and Dentistry, London, United Kingdom; ²University of Louisville, Louisville, Kentucky, United States; ³Centre for Evolution and Cancer, University of California, San Francisco, United States; ⁴Department of Pathology, Brigham and Women's Hospital, Boston, United States; ⁵Department of Histopathology, University College London Hospital, London, United Kingdom

Dysplasia in epithelia is an important histological diagnosis. The specific genetic changes which are responsible for the induction of this phenotypic change are unknown. Recent reports indicate that the dysplastic phenotype may not be immutable: in basal crypt dysplasia-like atypia (BCDA), unequivocal dysplastic changes are seen in the crypts in Barrett's esophagus and other pre-invasive lesions in the gastrointestinal tract, but the upper crypts and surface epithelium associated with these dysplastic crypts show the definitive morphology of a differentiated epithelium. The genotypic relationship between the BCDA and the differentiated surface epithelium is presently unclear. We obtained 17 examples of BCDA: the lower crypts and upper crypts and surface epithelium were differentially laser-microdissected from formalin-fixed, paraffin embedded sections and mutations were sought in tumour suppressor genes frequently associated with progression in Barrett's esophagus. We found two patients who both showed a c. C238T mutation in the p16 (CDKN2A, p16Ink4A) gene and where the precise microanatomical relationships could be discerned: this mutation was present in both the BCDA at the crypt base and in the upper crypt and surface epithelium. In BCDA, the dysplastic basal crypt epithelium and the upper crypt and surface epithelium show clonal mutations in p16, showing that the surface epithelium is derived from the dysplastic crypt

Detailed Programme – Tuesday 8 January 2013

Presenter = © · Abstract numbers are shown in bold and square brackets eg [S123]

epithelium: the dysplastic phenotype is therefore not fixed and can be reversed. The mechanism of this change is unclear: dysplastic cells may, probably at an early stage in their progression, respond to differentiation signals. We are some way from a definition of the genotypic correlates of the dysplastic phenotype, and from an understanding of its plasticity.

- 16.45–17.00 [PL6] **Implementing Next Generation Sequencing on Formalin-Fixed Paraffin-Embedded Tumour-Derived DNA for Mutation Analysis in Routine Molecular Diagnostic Pathology**
© D Sie; B Ylstra; PJF Snijders; B Diosdado; GA Meijer; DAM Heideman
VU University Medical Center, Amsterdam, Netherlands
Purpose of the study: One of the challenges in personalized cancer medicine is generating a comprehensive report on all relevant tumour biomarkers in a short period of time. To this end, technical developments in Next Generation Sequencing (NGS) have been made allowing us to analyze increasing number of biomarkers in parallel (>200 amplicons) while minimizing turnaround time (<2 days). Moreover, the developed protocols are suitable for using formalin-fixed paraffin-embedded (FFPE) specimens and low DNA input. The present study evaluates the performance of the Illumina MiSeq Personal Sequencer (MiSeq) together with the Illumina TruSeq Amplicon Cancer Panel (TSACP) on FFPE tissue-derived DNA for mutation analysis in routine molecular diagnostic pathology.
Methods: Fifty FFPE tissue-derived DNAs of lung and colon carcinomas (50-250ng) are subjected to the TSACP protocol prior to sequencing on the MiSeq. NGS data are compared to those of High Resolution Melting followed by Sanger sequencing (HRM-sequencing) for *EGFR*, *KRAS*, *PIK3CA*, and *BRAF* on the same series. The NGS system is evaluated for reproducibility, DNA input, number of informative assays, relative sensitivity and specificity, and turnaround time.
Summary of results: Analysis of 22 DNA samples shows informative results with input down to 150ng. Turnaround time of the TSACP protocol and sequencing is 2 days. In the series analyzed, the mutation status of *EGFR* (4 deletions, 2 insertions, 6 point mutations), *KRAS* (13 point mutations), *PIK3CA* (1 point mutation), and *BRAF* (1 point mutation) as assessed by TSACP-based NGS was in full concordance with HRM-sequencing.
Conclusions: TSACP-based NGS can be applied to minimal amounts of FFPE-derived DNA and performs equal to HRM-sequencing, allowing its use for mutation analysis in routine molecular diagnostic pathology. Studies are ongoing to also validate the method for translocation and copy number analysis.
- 17.00–17.15 [PL7] **Gene Expression Profiling of Post-Transplant Lymphoproliferative Disorder using Formalin-Fixed Tissue Samples**
© C Jones¹; RJ Byers¹; M Morton²; J Taylor³; S Usher¹; K Ryan²; J Adams²; B Coupes²; J Burthem¹; M Picton²; J Radford¹; K Linton¹
¹The University of Manchester, Manchester, United Kingdom; ²Manchester Royal Infirmary, Manchester, United Kingdom; ³Paterson Institute for Cancer Research, Manchester, United Kingdom
Post-transplant lymphoproliferative disorders (PTLD) arise following immunosuppression given to prevent graft rejection, in many cases through proliferation of EBV-transformed B-cells. However the pathogenesis of PTLD is poorly understood at the molecular level. Recent advances in gene expression profiling of archival diagnostic tissue have enabled investigation of the molecular basis of PTLD. We have performed a pilot gene expression analysis on a single centre renal transplant PTLD (n=28) series and de novo cases of diffuse large B cell lymphoma (DLBCL) (n=12) using RNA extracted from routinely processed diagnostic formalin-fixed paraffin embedded (FFPE) tissue and profiled on Affymetrix Human Exon 1.0 ST arrays.
Distinct gene expression clusters were observed for PTLD DLBCL (n=6) and de novo DLBCL (n=12), whilst PTLD DLBCL furthermore contained two distinct subgroups. These findings support the suggestion that PTLD DLBCL is genetically distinct from DLBCL arising in the immunocompetent patient. In this small study, the heterogeneous PTLD tumours (n=28) did not cluster according to histological subtype (2 early lesions, 11 polymorphic-PTLD, 15 monomorphic-PTLD) or EBV status at the time of PTLD diagnosis (18 +ve, 10 -ve) and it was not possible to identify genes differentially expressed between these groups.
The results confirm the heterogeneous nature of PTLD and its molecular distinction from B-cell lymphoma in immunocompetent patients. Whole transcriptome expression profiling of archival tissue has the potential to provide insights into disease pathogenesis, including a possible role for EBV-independent factors and exploration of whether PTLD develops across a continuum of early lesions to monoclonal lymphomas. The lack of genetic distinction between PTLD subtypes in this study underlines the heterogeneity of PTLD demonstrating the need for larger studies of uniform subtypes through UK wide collaboration.
- 17.15–17.30 [PL8] **A Functional Single Nucleotide Variant in Brachyury is Strongly Associated with Sporadic Chordomas.**
© AM Flanagan; N Pillay; MF Amary; R Tirabosco; D Halai; F Berisha
Royal National Orthopaedic Hospital, London, United Kingdom
Introduction: Brachyury is implicated in the pathogenesis of chordoma, which is nearly always a sporadic disease. In the rare familial form, a germline duplication of brachyury has been identified as a genetic susceptibility factor. Although somatic amplification (7% of cases) and minor allelic gain (13% of cases) of the brachyury locus is present in sporadic chordomas, susceptibility determinants in this cohort of patients are unknown.
Aim: To determine genetic susceptibility variants in patients with sporadic chordomas.

Detailed Programme – Tuesday 8 January 2013

Presenter = © · Abstract numbers are shown in bold and square brackets eg [S123]

Methods: 1. We performed high resolution arrayCGH on 23 sporadic chordomas to determine if a duplication of brachyury is a common event in this cohort. 2. We conducted a gene association study on 40 patients with chordoma and 358 ancestry-matched, unaffected individuals with replication in an independent cohort. Summary of results: Whole-exome sequencing revealed that the strongest candidate genetic risk factor was a common SNP (rs2305089) in exon 4 of brachyury. This finding was validated using Sanger sequencing and Taqman genotyping resulting in an allelic odds ratio (OR) =6.1, P=4.4x10⁻⁹, CI= 3.1-12.1. rs2305089 alters the DNA binding ability of brachyury. By using gene expression microarrays and qRT-PCR assays we show that the altered function of brachyury, caused by the SNP, is associated with different expression levels of brachyury and its downstream targets.

Conclusions: The heritability risk conferred by common genetic variants in cancers is generally modest (~1-2 fold). The finding of a per allele OR>5 is exceptional amongst those cancers for which there is a non-Mendelian mode of inheritance. In view of this, and the dearth of functional variants, other than rs2305089, there is a strong case that this SNP not only contributes significantly to the development of chordoma but also represents a novel example in a rare tumour of a strong risk allele that is prevalent in the general population.

17.30-17.35

AULA

PRESENTATIONS

1 — Pathological Society's Undergraduate Essay Competition Prize Winner 2012

Mr A Chhabra, Liverpool

2 — *Journal of Pathology* Jeremy Jass Prize for Research Excellence in Pathology 2011

Dr M Fernanda Amary, London

17.35–18.35

AULA

THE PATHOLOGICAL SOCIETY OF GREAT BRITAIN & IRELAND'S

9th GOUDIE LECTURE

Chair: Prof CS Herrington, General Secretary, Pathological Society and University of Dundee

[S5]

MALT Lymphoma: Many Pathways Lead to NF-κB Activation

© Prof MQ Du

Department of Pathology, University of Cambridge, Cambridge, United Kingdom

Mucosa-associated lymphoid tissue (MALT) lymphoma is typically derived from a background of chronic inflammatory disorder. At least in those from the stomach, chronic stimulation of the B-cell receptor and CD40, which activate the canonical and non-canonical NF-κB pathway respectively, is known to play a critical role in the lymphoma development.

Genetically, MALT lymphoma is characterised by recurrent, but mutually exclusive chromosome translocations: t(11;18)/API2-MALT1, t(1;14)/BCL10-IGH and t(14;18)/IGH-MALT1, which target a common molecular pathway. BCL10 and MALT1 activate the canonical NF-κB activation pathway, while the API2-MALT1 fusion protein activates both canonical and non-canonical NF-κB pathways. These translocations occur frequently in MALT lymphoma of the lung and stomach, but rarely or not in those of the ocular adnexa, salivary glands, thyroid and skin.

Genomic profiling of ocular adnexal MALT lymphoma (OAML) identified TNFAIP3 (A20), encoding a global NF-κB inhibitor, as the target of 6q23 deletion. Subsequent studies showed that A20 was frequently inactivated by deletion and/or somatic mutation in OAML and other lymphoma subtypes including ABC-DLBCL (activated B-cell like diffuse large B-cell lymphoma) that are characterised by constitutive NF-κB activation. Our ongoing investigation also demonstrated frequent activating mutations in MYD88, encoding a common adaptor for the IL1-R and TLR signalling, but not in CARD11, CD79A, CD79B and PRDM1 in OAML, which are frequently mutated in ABC-DLBCL. Both TNFAIP3 inactivation and MYD88 activation were associated with enhanced expression of NF-κB target genes in OAML.

In summary, MALT lymphoma of various anatomic sites is characterised by distinct genetic abnormalities that commonly activate NF-κB, providing genetic basis for design of future therapeutic strategy.

Partially supported by a Sino European Award from the Pathological Society.

19.00–22.30

STADSKASTEEL OUDEAN RESTAURANT · UTRECHT

BREWERY TOUR (19.00–20.00) and SOCIETY DINNER (20.00–22.30)

Detailed Programme – Wednesday 9 January 2013

Presenter = © · Abstract numbers are shown in bold and square brackets eg [S123]

- 07.45–09.00 **FOYER**
REGISTRATION AND COFFEE
- 08.30–15.30 **EIJKMANKAMER**
SLIDE SEMINAR CASE VIEWING: *Neuroendocrine Tumours*
Sponsored by Philips Digital Pathology
- 08.30–10.30 **AULA**
SYMPOSIUM: *Gastrointestinal Pathology*
Chair: Prof GJA Offerhaus, University Medical Center Utrecht
Prof P Quirke, University of Leeds
- 08.30–09.00 **[S6]** ***Pretumour Progression in the Gastrointestinal Tract***
© Prof Sir NA Wright
Barts and the London School of Medicine and Dentistry, London, United Kingdom
The origins of cancer, and the mechanisms of its progression, have been long debated. The process of progression to cancer is often aborted or stalled, many more pre-malignant or pre-invasive lesions occur than lesions with the full malignant phenotype. In the gastrointestinal mucosa we see many colorectal adenomas which never become invasive, pancreatic intra-epithelial neoplasia which does not progress, and in Barrett's esophagus dysplasia that does not advance to invasion and metastasis. A seductive explanation for such phenomena can be found in the evolutionary approach to cancer development and progression.
Neoplastic development may be driven by somatic evolution, where mutations occur in a cell which remains within the tissue and which provides an advantage for that cell and its progeny. In this way the mutation is selected, expands and the progeny of the cell persists within the tissue as a mutant clone. Further mutations lead to sequential selection and expansion of subsequent clones until the malignant phenotype is delivered. Thus mutation leads to genetic diversity and selection of mutations which increase the fitness of a mutant clone. In which case – how do such mutant clones expand? What are the drivers for clonal expansion? How do clones in these lesions interact with each other – do they compete or co-operate, and what mechanism leads to clonal dominance and selection for progression to invasion and metastasis? And especially, how early in neoplastic development can we recognise mutant clones? This presentation will address these questions with special reference to cancer arising in inflammatory bowel disease.
- 09.00–09.30 **[S7]** ***Molecular Screening for Colorectal Cancer in the Faeces***
© Prof GA Meijer
VU University Medical Center, Amsterdam, Netherlands
Early detection, and in particular programmatic population based screening is the most effective approach to reduce death from colorectal cancer. Internationally, most formal population based screening programs use stool based tests as these have been shown to be most cost effective. The immunochemical fecal occult blood test (iFOBT), also called fecal immunochemical test (FIT), is widely used for this purpose. It detects small traces of blood in stool, that can be come from bleeding tumors in the colon, by using an antibody based assay directed against hemoglobin. However, not all colon tumors bleed and therefore the FIT has a sensitivity that leaves room for improvement. Especially high-risk precursor lesions, i.e. advanced adenomas, are mostly left undetected by FIT. Additional markers that detect other tumour characteristics besides bleeding in the stool could increase this sensitivity and the chance of identifying a colon tumor. Molecular changes that result from the neoplastic process occur at the DNA level, and give rise to changes at RNA and protein level. These molecules can therefore be considered as reporters or biomarkers for increased risk of presence of CRC or its high-risk precursors. Examples include promoter methylation of the gene PHACTR3 identified in a bioinformatics approach and a number of proteins identified by LC-MS/MS by direct comparison of stool samples from CRC patients versus samples from colonoscopy negative controls. Large scale validation of these candidate markers on prospectively collected samples from screening populations are ongoing.
- 09.30–10.00 **[S8]** ***Mimics of Inflammatory Bowel Disease***
© Prof NA Shepherd
Cheltenham General Hospital, Cheltenham, United Kingdom
The term chronic inflammatory bowel disease (CIBD) tends to infer ulcerative colitis, Crohn's disease and/or the spectrum of pathology that lies between, encompassing indeterminate colitis and other cases of equivocal inflammatory bowel disease, now best termed IBDU in the context of biopsy material. There are an inordinate number of conditions, many of which bear the title 'colitis', which may show strong pathological mimicry CIBD and may be included under the umbrella term 'inflammatory bowel disease'. Infections, viral, bacterial and larger beasts, immunosuppression, radiation, ischaemia, diversion, diverticular disease, mass lesions, the effects of

Detailed Programme – Wednesday 9 January 2013

Presenter = © · Abstract numbers are shown in bold and square brackets eg [S123]

treatment, especially drugs, and various esoteric conditions may all produce intense mimicry of CIBD. It behoves the diligent pathologist to realise that the context of the biopsy appearances, in terms of clinical, microbiological, radiological and endoscopic features, is perhaps the single most important factor to ensure the appropriate final diagnosis.

The presentation will consider three main areas of controversy: namely, the relationship between CIBD and diverticular disease and the mimicry of the former by the latter. Secondly we will address the diagnosis and implication of a diagnosis of focal active colitis. There are four major publications on the latter. What is clear is that drugs and infection are the most likely cause but CIBD is the ultimate diagnosis in some 15% of cases of FAC. However, the latter becomes more likely if there are other histological features of CIBD, alongside the changes of FAC. Finally we will consider the ability of mass lesions of the intestines to mimic CIBD. Once again, the importance of context and correlation with the clinical and endoscopic features is paramount before a definitive diagnosis of CIBD is made.

10.00–10.30 [S9] **Serrated Polyps of the Colorectum**

© Prof FT Bosman

University of Lausanne Medical Center, Department of Pathology, Lausanne, Switzerland

The category of serrated polyps of the colorectum comprises of hyperplastic polyps, sessile serrated adenoma or polyp (SSA/P) and traditional serrated adenomas. SSA/P was accepted as a new entity in the 4th edition of the WHO Classification of tumours of the digestive system. Some, convinced of the premalignant character, insist on the term sessile serrated adenoma while others, even though accepting the capacity of some of these lesions to progress towards malignancy, consider that most will not progress and insist on the term sessile serrated polyp.

Remaining problems are the suboptimal inter-observer agreement in terms of the diagnosis and the question how frequent they progress to malignancy and how to recognise those that will. The reproducibility problem might be at least partly biological because if an SSA/P arises from a hyperplastic polyp it is conceivable to be confronted with a lesion that mostly looks like an HP but with a few crypts showing the characteristics of SSA/P.

SSA/P are usually larger (often >1 cm) than hyperplastic polyps and occur more frequently in the right colon. Crypt architecture is disturbed, with crypts dilated at the basis, branching out laterally leading to a boot-like or inverted T-like configuration. Cytonuclear characteristics include proliferative activity higher up in the crypts and goblet-cell differentiation already at the crypt basis. SSA/P can show features of dysplasia and then the term SSA/P with (low grade or high grade) dysplasia is used.

SSA/P develop through molecular pathways different from those involved in traditional adenomas of the colorectum and from traditional serrated adenomas. The lesions have deficient mismatch repair and are therefore microsatellite instable (MSI-H), due to hypermethylation silencing of MLH1. This goes along with frequent BRAF mutations.

10.30–11.00 **1ST FLOOR: SENAATZAAL & MASKERADEZAAL** **COFFEE AND TRADE EXHIBITION** **POSTER VIEWING — BELLE VAN ZUYLEN ZAAL, ZAAL 1636 & THE FOYER**

11.00–12.30 **AULA** **SYMPOSIUM: *Molecular Diagnostics***

Chair: Prof Sir NA Wright, Barts and The London School of Medicine
Prof Dr H Morreau, Leiden University Medical Center

11.00–11.30 [S10] **Using Functional Genetics to Optimise the Treatment of Cancer**

© Prof Dr R Bernards

Netherlands Cancer Institute, Amsterdam, Netherlands

Unresponsiveness to therapy remains a significant problem in the treatment of cancer, also with the new classes of cancer drugs. In my laboratory, we use functional genetic approaches to identify biomarkers that can predict responsiveness to targeted cancer therapeutics. Nevertheless, it remains poorly explained why a significant number of tumors do not respond to these therapies. We aim to elucidate the molecular pathways that contribute to unresponsiveness to targeted cancer therapeutics using a functional genetic approach. This will yield biomarkers that may be useful to predict how individual patients will respond to these drugs. Furthermore, this work may allow the development of drugs that act in synergy with the established drug to prevent or overcome drug resistance.

To identify biomarkers that control tumour cell responsiveness to cancer therapeutics, we use multiple complementary approaches. First, we use genome wide loss-of-function genetic screens (with shRNA interference libraries) in cancer cells that are sensitive to the drug-of-interest to search for genes whose down-regulation confers resistance to the drug-of-interest (resistance screens). In addition, we use shRNA screens to screen for genes whose inhibition enhances the toxicity of cancer drugs (sensitizer screens). As a third approach, we use gain of function genetic screens in which we search for genes whose over-expression modulates drug responsiveness. Once we have identified candidate drug response biomarkers in relevant cell line models, we ask if the expression of these genes is correlated with clinical response to the drug-of-interest. For this, we use tumour samples of cancer patients treated

Detailed Programme – Wednesday 9 January 2013

Presenter = © · Abstract numbers are shown in bold and square brackets eg [S123]

with the drug in question and whose response to therapy is documented.

In a fourth and distinct approach we perform high throughput sequencing of the “kinome” (some 600 genes) of tumour samples to identify connections between cancer genotype and drug responses.

Examples of some of these approaches to identify biomarkers of response to different cancer drugs will be presented.

11.30–12.00 [S11] ***Molecular Diagnostics in Melanoma***

© Dr WAM Blokx

UMC St Radboud, Nijmegen, Netherlands

The past 10-15 years have dramatically improved the insight into cytogenetic mechanisms involved in melanocytic tumours. In diverse subtypes of nevi and melanoma different mutation spectra have been demonstrated involving mostly genes in the MAPK /ERK and the PI3K/AKT pathways.

Roughly in melanoma we now can identify two major subgroups of melanomas. The first group of melanomas, is the one that develops from epithelium associated melanocytes, such as the cutaneous and mucosal melanomas in which BRAF, NRAS and KIT mutations are present. The second group consists of melanomas originating from non-epithelium associated melanocytes, such as the uveal and primary brain melanomas. These melanomas characteristically contain oncogenic mutations in the GNAQ and GNA11 genes.

Especially BRAF mutations have gained a lot of attention due to dramatic responses of BRAF mutated melanomas to specific inhibitors. Several other targeted therapies such as MEK inhibitors and KIT targeted therapy in melanoma are exploited and the expectation is that developments will be rapid in this field.

A major problem in targeted therapies is the development of resistance. The development of combinations of different targeted therapies or targeted therapies with other treatment modalities such as immunotherapy is therefore mandatory.

Pathologists have and will keep an important role in diagnosing metastatic melanoma, and in properly guiding molecular testing pre- and post-treatment. This lecture will give an update on cytogenetics in melanocytic tumours and melanoma, and how this knowledge can facilitate diagnosis, and establishment of prognosis and best treatment options.

12.00–12.30 ***Molecular Diagnostics in Lung Cancer Treatment***

Prof Dr HJM Groen

University Medical Center, Groningen

12.30–14.00 **1st FLOOR: SENAATSZAAL & MASKERADEZAAL
LUNCH AND TRADE EXHIBITION
POSTER VIEWING — BELLE VAN ZUYLEN ZAAL, ZAAL 1636 & THE FOYER**

13.00–14.00 **AULA**

MEET THE EXPERTS TRAINEES SESSION: *Gastrointestinal Stem Cells*

Chair: Dr NP West, Chair Pathological Society Trainees' Sub-committee; Leeds Institute of Molecular Medicine, St James's University Hospital, Leeds
Dr R Leguit, University Medical Center Utrecht

[S12] ***Lgr5 Stem Cells in Self-renewal and Cancer***

© Prof JC Clevers

Hubrecht Institute, Royal Netherlands Academy of Arts and Sciences & University Medical Centre Utrecht, Utrecht, Netherlands

The intestinal epithelium is the most rapidly self-renewing mammalian tissue. *Lgr5* is a gene transcribed in cycling, crypt base columnar cells at the crypt base. Using lineage tracing experiments the *Lgr5*⁺ cells were identified as the stem cells of the intestinal epithelium. Furthermore, *Lgr5*⁺ stem cells can initiate ever-expanding organoids in vitro. The *Lgr5*⁺ stem cell hierarchy of differentiation is maintained in these organoids. Thus, intestinal crypt-villus units can be built from a single stem cell in the absence of a non-epithelial cellular niche.

Although, *Lgr5* stem cells persist life-long, crypts drift toward clonality quickly. The cellular dynamics are consistent with a model in which the stem cells divide symmetrically, and stochastically adopt stem or transient amplifying cell fates after cell division.

Lgr5 stem cells are interspersed between differentiated Paneth cells, which produce all essential signals for stem-cell maintenance. Co-culturing of sorted stem cells with Paneth cells dramatically improves organoid formation. Genetic removal of Paneth cells in vivo results in the concomitant loss of *Lgr5* stem cells.

Intestinal cancer is initiated by Wnt pathway-activating mutations in genes such as APC. Deletion of APC in stem cells, but not in other crypt cells results in neoplasia, identifying the stem cell as the cell-of-origin of adenomas.

Moreover, a stem cell/progenitor cell hierarchy is maintained in stem cell-derived adenomas, lending support to the “cancer stem cell”-concept.

Detailed Programme – Wednesday 9 January 2013

Presenter = © · Abstract numbers are shown in bold and square brackets eg [S123]

14.00–14.45

AULA

SLIDE SEMINAR DISCUSSION SESSION: *Neuroendocrine Tumours*

Chair and Cases submitted by:

Dr S van Eeden, Academic Medical Centre, Amsterdam

Dr MLF van Velthuysen, The Netherlands Cancer Institute, Amsterdam

14.45–15.30

AULA

KEYNOTE LECTURE

Chair: Prof PJ van Diest, University Medical Center Utrecht

[S12] *Lgr5 Stem Cells in Self-renewal and Cancer*

© Prof JC Clevers

Hubrecht Institute, Royal Netherlands Academy of Arts and Sciences & University Medical Centre Utrecht, Utrecht, Netherlands

The intestinal epithelium is the most rapidly self-renewing mammalian tissue. *Lgr5* is a gene transcribed in cycling crypt base columnar cells at the crypt base. Using lineage tracing experiments the *Lgr5*⁺ve cells were identified as the stem cells of the intestinal epithelium. Furthermore, *Lgr5*⁺ve stem cells can initiate ever-expanding organoids in vitro. The *Lgr5*⁺ve stem cell hierarchy of differentiation is maintained in these organoids. Thus, intestinal crypt-villus units can be built from a single stem cell in the absence of a non-epithelial cellular niche.

Although, *Lgr5* stem cells persist life-long, crypts drift toward clonality quickly. The cellular dynamics are consistent with a model in which the stem cells divide symmetrically, and stochastically adopt stem or transient amplifying cell fates after cell division.

Lgr5 stem cells are interspersed between differentiated Paneth cells, which produce all essential signals for stem-cell maintenance. Co-culturing of sorted stem cells with Paneth cells dramatically improves organoid formation. Genetic removal of Paneth cells in vivo results in the concomitant loss of *Lgr5* stem cells.

Intestinal cancer is initiated by Wnt pathway-activating mutations in genes such as APC. Deletion of APC in stem cells, but not in other crypt cells results in neoplasia, identifying the stem cell as the cell-of-origin of adenomas. Moreover, a stem cell/progenitor cell hierarchy is maintained in stem cell-derived adenomas, lending support to the “cancer stem cell”-concept.

15.30

TEA

CLOSE OF MEETING

Acknowledgments (Trade Exhibition)

as at time of going to press

The Pathological Society of Great Britain & Ireland wishes to acknowledge the support of the following companies participating in the TRADE EXHIBITION

Dako UK Ltd

Founded in 1966, by Doctor Niels Harboe, Dako introduced reliable immunohistochemical tests in clinical pathology. Tumour-differentiation was now a fact. Throughout its existence Dako built up a reputation based upon quality, innovation, service and know-how.

EPOS, EnVision, pharmDx (Herceptest), FLEX RTU antibodies and DakoLink integration are only Dako's most famous innovating techniques which allowed Dako to change and improved diagnostics in Pathology. Dako still continues to do this. Being a partner of clinical pathology laboratories on the one side and pharmacy companies on the other, it is Dako's mission to set and redefine the standards for quality, TAT, cost-efficiency and productivity, as well as preserving our position as most important diagnostic company in the area of pharmacodiagnostica.

GE Healthcare Omnyx Digital Pathology*

The product line Omnyx provides a fully integrated, scalable, digital pathology solution designed to address the scale, reliability and workflow requirements of hospitals worldwide.

- High-throughput scanner with patented dual sensor scanning
- One touch – walk away scanner technology
- Innovative pathologist workstation – advanced reading workflow
- Whole slide image viewing with high effective streaming
- Connects labs and enables shared workflows, remote and home reading

To learn more about Omnyx Digital Pathology please visit www.gehealthcare.com/omnyx

** Unreleased product. MDD conformity assessment pending.
Product has not been evaluated by the FDA.*

Hologic

Hologic and Gen-Probe have long standing histories as companies ethically, emotionally and financially committed to improving healthcare outcomes on a global basis. We share complementary technologies and a common vision: to help save lives through early detection, improved diagnosis and less invasive treatments. The integration of Gen-Probe's established products, platforms and capabilities in research and development allows Hologic to push the boundaries of molecular diagnostics. At the same time, it advances our focus on women's health by expanding our ability to deliver the critical patient information needed to make informed clinical decisions, from the lab to the point of care.

Kreatech Diagnostics

Kreatech Diagnostics offers the broadest commercial portfolio available of Fluorescent in Situ Hybridization (FISH) probes: more than 400 REPEAT-FREE™ POSEIDON™ probes.

Kreatech continually strives to increase the level of customer and technical service as we are committed to delivering high-performance and innovative products in biology, research and microarray labelling.

Kreatech has the expertise to develop new probe designs based on your specific needs and specifications.

The company initially focused on developing its unique technology platform, Kreatech's proprietary non-enzymatic Universal Linkage System (ULS™) for microarray labeling applications. Additionally, Kreatech's technology is utilized to develop and produce its unique Repeat-Free Poseidon FISH probes.

Acknowledgments (Trade Exhibition)

as at time of going to press

Life Technologies Corporation

Life Technologies Corporation is a global biotechnology company dedicated to improving the human condition. Our systems, consumables and services enable researchers to accelerate scientific and medical advancements that make life even better.

Our customers do their work across the biological spectrum, working to advance the fields of discovery and translational research, molecular medicine, stem cell-based therapies, food safety and animal health, forensics.

The company manufactures both molecular diagnostic and research use only products. Life Technologies' includes innovative instrument systems under Applied Biosystems and Ion Torrent and the broadest range of reagents with its Invitrogen, GIBCO, Molecular Probes and Taqman products.

PathXL

PathXL specialises in web-based software and workflows for Digital Pathology. Its PathXL® Manager product provides a robust, secure and open web-based platform to enable digital pathology users across all fields to manage, view and collaborate around virtual slides easily and efficiently. In addition, PathXL provides a range of applications and workflows on top of PathXL® Manager to deliver specific solutions to pathologists, scientists and students in Education, Research, Clinical and Biobanking settings. PathXL also provides a full range of supporting services, including scanning, hosting, image analysis and consultancy. PathXL is a privately owned company, headquartered in Belfast, Northern Ireland.

For more information please visit: www.pathxl.com

Philips

Designed around the needs of pathologists, Philips offers an integrated Digital Pathology Solution.

The solution comprises of the Philips Ultra Fast Scanner (UFS) and Image Management System (IMS). The UFS is easy to use and creates whole slide images of exceptional quality in less than 60 seconds per slide (40x equivalent, 15 x 15 mm scan area). The IMS is designed for speed and ease of use: supports fast and efficient workflow with bi-directional integration of the Laboratory Information System. Visit us and learn more about powerful sharing tools that allow real-time collaboration with colleagues anywhere in the world.

Tispa Medical

Tispa Medical – *The new standard in tissue processing.*

- **Toxic free** reagents, just ethanol, CO2 and paraffine.
- Uses **fresh reagents each run**, generating constant quality in residual water and shrinkage, substantially reducing the risk of cross samples contamination.
- **Gentle process**, indications are that this leads to higher antigenicity, possible to dilute some immuno's from 1/100 to 1/800.
- **Fast process cycles**, 1,5h for biopsies, 3,5h for normal size tissues, 4,5h for up to 5mm fatty tissue.

Poster Abstracts

Presenter = ①

P1

Unexpected Autopsy Findings in a Stroke Patient

© DM Alexe¹; I Said¹; DG O'Donovan²; MG Dura²; U Pohl²

¹Royal London Hospital, London, United Kingdom; ²Queen's Hospital, Romford, United Kingdom

Background: Intravascular (angiotropic) lymphoma is a rare haematological neoplasia, which is rarely diagnosed in life. It is a systemic disease resulting from a monoclonal proliferation of lymphoid cells (B or T cells) within the lumen of small arteries, arterioles, capillaries and venules with subsequent occlusion and tissue infarction. Diagnosis of intravascular lymphoma is difficult as it can clinically mimic many diseases, including neurological, renal, endocrine, or cutaneous. Paraclinical investigations usually show non-specific findings.

Aim: We are presenting the case of a 67 year old gentleman who was admitted to hospital with neurological symptoms. He was diagnosed and treated for transitional ischaemic cerebral episodes. During his last admission, he developed aspiration pneumonia and died. A post-mortem investigation was requested by the team looking after the patient in order to exclude intra-abdominal pathology as his serum lactic acid levels were high.

Major findings: Post-mortem investigation revealed a disseminated predominantly intravascular infiltration by a neoplastic population of atypical large lymphoid cells. Apart from the extensive involvement of the brain and adrenal glands, kidneys, and perinephric fat, lympho-reticular organs and the pituitary gland were also severely involved.

Neoplastic cells showed marked cellular atypia and were strongly positive for the B-cell markers CD20 and CD79a, Mum1, and bcl-2. Ki67 proliferation marker was over 80%. These features were of an intravascular malignant large cell lymphoma of B-cell origin.

Learning points: Intravascular lymphoma is a rare disease and diagnosis in life can be very difficult. It is important, however, to consider this possibility in the differential diagnosis of patients who present with manifestations of systemic disease. If treated early in the evolution of the disease, intravascular lymphoma may respond to chemotherapy.

P2

Intestinal Obstruction from Severe Ascariasis: a Postmortem Case Report.

IM Onwubuya; © A Anjorin

Obafemi Awolowo University Teaching Hospitals Complex, Ile-Ife, Nigeria

Ascariasis, a soil transmitted roundworm infestation is still a serious health problem in tropical countries like Nigeria and particularly infests preschool and young children in low socioeconomic settings.

Heavy infestation is associated with growth retardation and poor cognitive function but mortality could result from intestinal obstruction by a ball of worms and this possibility should be kept in mind when a child presents with sudden onset abdominal pain. This would require urgent treatment if mortality is to be averted.

Health systems focus now on Human Immunodeficiency Virus infection scourge and other diseases like malaria with the result that policies like mass de-worming schemes are fast disappearing.

We present a case of a three year old boy from a low income family in a rural area in Ile-Ife, who presented at the emergency department of our hospital with signs and symptoms of intestinal obstruction and hypermetabolic state and dying within three hours of presentation with autopsy findings of small bowel obstruction from overwhelming ascariasis infestation by over two hundred adult worms.

P3

A New Method to Discriminate Between Vital and Post Mortem Injury Wounds: A Probability Scoring System using Antibodies Against CD62p, Fibronectin and Factor 8.

FRW van de Goot¹; © HI Korkmaz²; J Fronzcek²; MPV Begieneman²; L Rozendaal²; B Witte²; R Paul²; PAJ Krijnen²; JWM Niessen²

¹NFI, The Hague, Netherlands; ²VU Medical Center, Amsterdam, Netherlands

Purpose of the study: In forensic autopsies it is important to differentiate between vital and post mortal wounds. Although immunohistochemical analysis has improved diagnosis of a vital wound, the golden standard still is unknown. The aim of this study was to develop a probability scoring system using three known immunohistochemical markers, namely CD62p, fibronectin and Von Willebrand factor (Factor 8), to discriminate between vital and post mortem injury.

Methods: Tissue samples of mechanically induced skin injuries of known wound age, varying from post mortem wounds to vital wounds of up to 30 minutes old, were obtained at autopsy (n=793). Tissue samples were divided in three different groups: (A) non injured control skin, (B) injuries inflicted shortly before death (several seconds up to a minute), (C) injuries inflicted 15-30 minutes before death. Wounds were immunohistochemically analyzed and scored for the expression of CD62p, fibronectin and Factor 8; 0 = negative, 1 = minor, 2 = moderate, 3 = strong expression.

Summary of results: In control tissue (A) we found minor expression of CD62p, Fibronectin and Factor 8. The expression of these markers increased gradually, but significantly in <1 min. (B) up to 15-30 min. (C) old wounds. The probability scores for respectively CD62p, Fibronectin and Factor 8 were: in case a score 0, a 88%, 85% and 99% chance of a wound to be post-mortem, in case a score 1, a 77%, 79% and 71% chance of a wound to be < 1 min. old, in case a score 2, a 61%, 70% and 78% chance of a wound to be < 1 min. old and in a case score 3, a 72%, 56% and 47% chance of a wound to be 15-30 min. old.

Conclusions: We have developed a probability scoring system using a combination of three immunohistochemical markers which will strengthen the differentiation between post mortem and vital wounds.

P4

Distant Recurrence Risk Assessment in Early Invasive Breast Cancer: an Immunopanel Algorithm Formed of p53, HER2/neu, and BCL2

© MA Aleskandarany¹; AR Green¹; EA Rakha²; D Soria³; IO Ellis¹

¹Division of Pathology, School of Molecular Medical Sciences, Nottingham University, Nottingham, United Kingdom; ²Department of Pathology Nottingham University Hospitals NHS Trust, Nottingham, United Kingdom; ³School of Computer Science, The University of Nottingham, Nottingham, United Kingdom

Background and purpose: Distant recurrence (DR) is the most lethal form of recurrence in breast cancer (BC) patients. Accurate DR prediction is critical for accurate risk stratification and effective treatment decision making. Many prognostic markers/models based on tissue marker studies are continually emerging; however, very few of them have fulfilled satisfactory evidences for clinical applications. This study aimed at building an algorithm for DR risk assessment in BC patients.

Methods: A well-characterised series of early invasive primary operable BC (n=1902), with immunohistochemical (IHC) data of a broad panel of biomarkers of clinical and biological relevance to BC biology and progression formed the material of this study. A probabilistic decision tree algorithm was computed using WEKA software, utilising the H-score or percentage expression of 15 biomarkers, and the metastatic status (DM Yes/No), with minimum number of cases in each branch to be equal or more than four.

Summary of results: According to the decision tree, four risk groups of patients were characterised. Three markers; p53, HER2 and BCL2 were able to predict the probability of DR in the studied set, based on software-generated cut-offs. The algorithm precision rate in predicting DR, was 26/32 = 81.1%, for positive predictive value and 150/194 = 77.3%, for the negative predictive value.

Conclusions: This algorithm reiterates the reported prognostic values of these three markers and underscores their central biologic role in BC progression. According to these results, this pruned panel of biomarkers could be used with acceptable success in DR prediction. However, model performance warrants further independent validation.

P5

Epithelial Mesenchymal Transition in Early Invasive Breast Cancer: Further Evidence Using Reverse Phase Protein Array

© MA Aleskandarany¹; OH Negrin²; EA Rakha¹; MA Ahmed³; CC Nolan³; PJ Tighe²; AR Green³; IO Ellis¹

¹Department of Pathology Nottingham University Hospitals NHS Trust, UK, Nottingham, United Kingdom; ²Division of Immunology, University of Nottingham, UK, Nottingham, United Kingdom; ³Division of Pathology, School of Molecular Medical Sciences, Nottingham University, UK, Nottingham, United Kingdom

Background and purpose: Although Epithelial Mesenchymal Transition (EMT) has been reported in-vivo, the occurrence of events remains unclear. This study aimed to explore the EMT portraits of breast cancer (BC) with relevance to different molecular pathways and molecular subtypes.

Methods: Hierarchical and k-means clustering analyses were performed on a well-defined series of invasive BC (n=1656), prepared as tissue microarrays, utilising data of an immunohistochemical (IHC) biomarkers including cadherins, TGFβ1, PIK3CA, pAkt, cytokeratins, Twist2, Erb-family members and hormone receptors. Reverse phase protein array (RPPA) was performed on protein extracts from formalin-fixed paraffin-embedded tissues of a subset of cases from the same series (n=49).

Summary of Results: Within the molecular subtypes (Luminal 1&2, HER2+, and basal-like (BLBC)), there was differential IHC expression of EMT markers. BLBC tended to express lower E-cadherin, higher P-cadherin, SMA and PIK3CA, relative to HER2+ BC that expressed highest levels of N-cadherin, TGFβ1 and PIK3CA. Although distribution of EMT markers/triggers using RPPA was not statistically significant, their mean levels were variably expressed within BC molecular classes. E-cadherin was reciprocally expressed with N-cadherin in luminal and HER2+ BC. Moreover, pAkt-S473 was maximally expressed in luminal BC and minimally expressed in TN-basal BC, while PIK3CA was maximally expressed in HER2+. However, TGFβ1 was maximally expressed in TN-Basal class, followed by HER2+ BC.

Conclusions: EMT in BC appears to occur in synergy with TGFβ1 and PIK3/Akt pathways activation. RPPA findings validate quantitatively the findings observed using IHC, therefore opening promising avenues for monitoring subtle quantitative changes in protein expression.

P6

Metasin-BLNA, the NHS Solution for the Intra-operative Assessment of Sentinel Lymph Nodes from Breast Cancer Patients: The Multi-centre Validation of 1265 Cases

© V Sundaresan¹; S Al-Ramadhani²; P Sai-Gridar³; D George¹; A McDowell⁴; S Holt³; S Jader¹; F Gabrielle⁴; I Cree⁴; R Salgado⁵; D Larsimont³; M Keshtgar⁶; M Jeffreys⁴; R Mansel⁷; M Morgan FRCS¹; S Bustin²

¹Princess Alexandra Hospital NHS Trust, Harlow, United Kingdom; ²Barts and the Royal London Hospital, London, United Kingdom; ³Prince Philip Hospital, Llanelli, Wales, United Kingdom; ⁴Queen Alexandra Hospital, Portsmouth, United Kingdom; ⁵Jules Bordet, Brussels, Belgium; ⁶Royal Free Hospital, London, United Kingdom; ⁷Cardiff University Hospital, Cardiff, Wales, United Kingdom

Surgical management of breast cancer has traditionally involved lymph node dissection with resultant morbidity. Current practice is to advocate axillary clearance if the sentinel node is positive for cancer. Assessment of the sentinel node status intra-operatively enables immediate axillary clearance. Frozen section and DAB cytology are available in this intraoperative setting. However both methods have disadvantages.

Here, as an alternative, we describe the validation of Metasin, a novel real time PCR assay for the detection of metastatic cancer in sentinel lymph nodes from breast cancer patients. There are 2 predictive markers: CK19 and Mammaglobin with PBGD as an internal reference gene.

Methods: Stored lymph node homogenates and RNA samples were examined by Metasin from 5 institutions from within the UK, (n=1265) and compared to the histological findings.

Results: Overall concordance between Metasin and histology was seen in 1192 of 1265 cases (94%). Discordant rate was 51 of 1265 cases (4%).

Macro/Micro determination: Using Metasin we were able to determine macro and micro-metastasis in 217 of 248 cases: 191 macro-mets (77%) and 26 micro-metastasis (10.5%). 4% of histologically macro-metastases were deemed micro-metastases by Metasin and 8.5% of macro-metastases by Metasin were reported as micro-metastases by histology.

Conclusion: Metasin BLN showed a sensitivity of 92%, a specificity of 97% and an accuracy of 96%. The PPV is 90% and the NPV is 98%. The results presented indicate an advantage over conventional histological analysis enabling immediate axillary clearance for patients with positive sentinel nodes.

P7

The Metasin-BLNA, intra-operative assessment of Sentinel Lymph Nodes from Breast Cancer Patients: CE Marking of the Metasin Assay for wider use

D George¹; A McDowell²; P Sai-Gridar³; S Holt FRCS³; G Gabrielle²; M Jeffreys²; M Balhause⁴; O Landt⁴; © V Sundaresan¹

¹Princess Alexandra Hospital NHS Trust, Harlow, United Kingdom; ²Queen Alexandra Hospital, Portsmouth, United Kingdom; ³Prince Philip Hospital, Llanelli, Wales, United Kingdom; ⁴TIB Molbiol, Berlin, Germany

Introduction: Intra-operative assessment of the sentinel nodes enables immediate axillary clearance. In a companion abstract, we have described a novel assay: the Metasin assay for detection of metastatic disease in the intra-operative setting. Here we describe the CE marking of this assay.

Metasin is a novel real time PCR assay for the detection of metastatic cancer in sentinel lymph nodes from breast cancer patients, with 2 predictive markers: CK19 and Mammaglobin with PBGD as an internal reference gene.

Materials and Methods: 1000 lymph nodes obtained from patients undergoing sentinel node biopsy from patients from 3 sites in the UK. Cases were selected with positives in preference to negative axillary clearances in order that the assay is able to detect metastatic disease.

Results: 767 lymph nodes were obtained from 3 sites: Lyophilised pre-mixes prepared commercially. These reagents were compared to reagents prepared in-house. Of the 767 nodes there was concordance of result between in-house reagents and Lyophilised reagents for all but 10 of 767 nodes. Discordance between lyophilised pre-mix reagents and in-house reagents are 0.9 %. Discordance between histology and lyophilised pre-mix reagents and in-house prepared reagents are 5.4 % and 5.6% respective prior any form of discordant analysis.

Conclusion: Published data indicates these results are well within the acceptable 7% discordance due to tissue allocation bias. The assay is accurate, fast (26 mins machine run time with over 75% of results being delivered in under 40 mins), reliable, cheap, providing value for money and easy to implement within a District General Hospital setting.

P8

Concordance of a Diagnosis of DCIS Using Vacuum Assisted Biopsies of the Breast Cancer with the Final Pathology

© ME Booth¹; N Sharma²; D Dodwell³; R Millican-Slater¹; S Lane¹; ET Verghese¹; AM Hanby¹

¹Department of Histopathology, St James University, Leeds, United Kingdom; ²Department of Radiology, St James University, Leeds, United Kingdom; ³Department of Oncology, St James University Hospital, Leeds, United Kingdom

BACKGROUND: The diagnosis of low grade DCIS is usually made on needle core biopsy. However, in certain situations, for example, where the standard core biopsy has not been representative, a vacuum assisted biopsy (VAB) might be necessary. This will yield more tissue for the pathologist to come to a more accurate diagnosis.

AIM: This study was designed to identify all VAB procedures that occurred in a large university hospital in the last 10 years and measure the concordance between the diagnosis of DCIS on VAB and the diagnosis following surgical excision.

METHODS: Pathology and clinical databases were searched for the terms "VAB", "Vacuum assisted biopsy" or "mammotome," from 2002 to 2012. The diagnosis using VAB and the final diagnosis of the surgical excision specimen were collected. In addition, key clinical and radiological parameters of LG-DCIS and IG-DCIS were reviewed.

RESULTS: There were 464 VAB procedures; 28 B1, 155 B2, 147 B3, 7 B4, 77 B5a and 22 B5b. Of the 77 B5a, 9 were low grade, 34 intermediate grade, 30 high grade and 4 were not graded. We excluded patients with multiple lesions or with no follow up data. 2/8 (25%) low grade, and 4/31 (13%) intermediate grade went on have a higher grade DCIS in the excision specimen. In addition, 1/8 (13%) low grade, 4/31 (13%) intermediate grade and 8/26 (31%) high grade DCIS lesions were upgraded to invasive carcinoma in the subsequent excision (Overall Kappa=0.6). One LG-DCIS that was upgraded to only a HG-DCIS had a positive SLB. None of the patients with LG-DCIS and 4 patients with IG-DCIS had a radiologically or clinically detectable mass. The extent of calcification ranged from 10-50 mm for LG-DCIS and 3-70 mm for IG-DCIS.

CONCLUSION: There was good agreement between the diagnosis of DCIS on VAB and the final surgical excision specimen.

P9

Palpable Ductal Carcinoma in Situ of the Breast

© R Verma; S Sundara Rajan; N Sharma; M Lansdown; AM Shaaban

Leeds Teaching Hospitals NHS Trust, Leeds, United Kingdom

Ductal carcinoma in situ represents 20–25% of malignancy detected at mammographic screening. Palpable pure DCIS (pDCIS) however, remains a rare entity. The aim of this study was to evaluate the incidence and pathological features of pDCIS.

Patients diagnosed with pDCIS from January 1999 to December 2011 were identified from electronic pathological database. During the study period, 669 cases of DCIS was diagnosed and 66 (9.8%) were pDCIS (Mean age=57 years (SD ±15.25)).

Mean size of the pDCIS was 37.2 mm (SD ± 29.96), majority were high grade (69%) and associated with comedo necrosis (61%). Mixed histological type was the commonest (40%) followed by solid (24%), papillary (21%), cribriform (11%) and others (4%).

Surgical excision showed small foci of invasion in 10 cases (14.9%). The mean size of pDCIS was higher in the latter group of patients (49mm, SD ± 27.5, p=0.15) with 80% being grade 3 and 90% having comedo necrosis. VNPI score was more than 4 in majority of the patients with pDCIS (81%).

Sixty one percentage of the tumours were ER positive and 39% were ER negative. Her2 was tested in only 11 patients and was positive in 6 (56%).

Mastectomy was performed in 55% and breast conservation achieved in the rest. Axillary surgery was performed in the majority (56%) with micrometastasis identified in a single patient, who was also found to have small invasive disease (3mm) on therapeutic excision. Adjuvant radiotherapy was administered in 31% and adjuvant hormonal treatment in 14%. One patient developed local recurrence after mastectomy and the rest remains disease free with a median follow-up of 60 months.

pDCIS is generally associated with more aggressive pathological features such as high grade, comedo necrosis and negative hormone receptors. Following a core biopsy diagnosis, thorough histological examination of the excision specimen is warranted to look for evidence of invasion or micro-invasion.

P10

A Two-tiered Approach as an Adjunct to Existing Intraoperative Metasin-BLNA in Detection of Metastatic Breast Cancer in Sentinel Lymph Nodes for Breast Cancer.

© PP Gopinath; D George; V Sundaresan

Princess Alexandra Hospital NHS Trust, Harlow, United Kingdom

Purpose of the study

Current breast cancer management is influenced by sentinel lymph node status (SLN). Intraoperative analysis of SLN can avoid a second operation. Metasin, a molecular assay with a high sensitivity has already been implemented. Tissue allocation bias (TAB) is generally accepted as the cause for discordance. The sensitivity of this assay could be greatly improved by sampling the whole node. A second tier of breast specific markers has previously been tested outside of the intraoperative setting as a fail safe and thereby enabling the whole SLN to be used for Metasin assay (see companion abstract).

Methods

A selection of 39 (57 nodes) SLN positive cases and 13 (49 nodes) negative cases (106 nodes in total) from the existing cohort of 1265 nodes were used for RT-PCR analysis of B305D, PIP1, GABA-D and B726R.

Summary of Results

Preliminary data indicates this approach is feasible. PIP1 was positive in 42% of positive SLN (24/57, 16 cases) and none of negative nodes (0/49). Of these PIP1 positive cases, 100% had macro-metastasis in SLN (15/16) and/or axillary clearance (1/16). 76% of PIP1 positive cases had extra-nodal spread (13/16). There were significant correlations between PIP1 positivity, macro-metastasis and extra-nodal spread (p<0.001).

Conclusions

The second cluster of markers could provide the fail safe if implemented in the post-operative setting, facilitating the examination of the whole SLN. We propose to apply this second tier of markers to the wider cohort of cases with the initial focus being discordant cases and later extending the study to include histology and molecular positive cases.

P11

Analysis of Copy Number Changes on Chromosome 16q in Male Breast Cancer by Multiplex Ligation-dependent Probe Amplification

© MM Lacle¹; PJ van Diest¹; H Buerger²

¹University Medical Center Utrecht, Utrecht, Netherlands; ²Institute of Pathology Paderborn/Höxter and Brustzentrum Paderborn, Paderborn, Germany

Gene copy number changes play an important role in carcinogenesis and could serve as potential biomarker for prognosis and potential target for molecular therapy.

Previous studies in male breast cancer (MBC) showed clear differences in gene copy number changes when compared with female breast cancer (FBC). This emphasizes the importance of identifying biomarkers and therapeutic targets that could aid in clinical management of MBC. Copy number changes mapping to chromosome 16 have been reported to be the most frequent alteration observed in breast cancer and a loss on the long arm of chromosome 16 has been shown to be associated with low grade and better prognosis in FBC. In the present study we aimed to further characterize copy number changes on the long arm chromosome 16 in a group of 135 MBC using a newly developed multiplex ligation-dependent probe amplification kit.

Hundred and twelve out of 135 (83% MBC showed copy number changes of at least one gene on 16q, mostly loss of 16q (71/135; 52.6%), either partial (66/135; 48.9%), or whole arm loss (5/135; 3.7%). This is much less often than previously described for female breast cancer. Copy number loss of genes on 16q was significantly correlated with favourable clinicopathological features: loss of CYLD, RBL2, MMP2, SLC12A3, GPR56, CDH1, MLYCD, IRF8, SPG7 and FANCA with negative lymph node status; loss of GPR56 with small tumour size, and RBL2 with low grade. A combination of 16q loss and 16q gain correlated even stronger with negative lymph node status (n=112; p=0.012), which was also underlined by unsupervised clustering. Copy number changes on 16q had no prognostic value. In conclusion, copy number loss on 16q and gain on 16p identify a group of MBC tumours with low propensity to develop lymph node metastasis. Although most MBC are of Luminal intrinsic type, loss on 16q is much less frequent in MBC than in FBC.

P12

Intraductal Chemotherapy in the Prevention of Breast Cancer

© JS de Groot; EJ Vlug; M van Amersfoort; X Pan;

E van der Wall; PJ van Diest

UMC Utrecht, Utrecht, Netherlands

Mutation of BRCA1 predisposes to the development of breast cancer with a lifetime breast cancer risk of over 60%. The only preventive option is bilateral prophylactic mastectomy. This mutilating procedure leads to a significant but incomplete reduction in breast cancer risk. Since the nipple provides direct access to the mammary ductal system, it could provide as an alternative strategy to prevent breast cancer. Intraductal (ID) administration of chemotherapy via the nipple could lead to ablation of cancer-prone mammary cells, thus preventing the formation of breast cancer.

To study the effect of ID chemotherapy on the non-diseased breast, postbreeder wild type female mice were treated twice with cisplatin or control by ID injection. The effect of cisplatin on mammary gland architecture and lobulo-alveolar development during pregnancy was analysed. To investigate whether cisplatin treatment affected normal mammary outgrowth, mammary epithelial cells (MECs) were isolated and transplanted in recipient mice using a cleared fat pad assay. FACS analysis was done to assess the effect on the distribution of mammary cell populations. After transplantation, a significant reduction in outgrowth of the transplanted MECs into a ductal network in cisplatin versus control treated glands was observed (p=0.008). Moreover, a significant reduction in the basal population of the epithelial cells was observed in cisplatin versus control treated glands (p=0.002). In pregnant mice, all control glands showed lobulo-alveolar development in the complete gland. However, in 53% of the cisplatin treated glands the fat pad was partially or totally devoid of mammary ducts. From these results we conclude that ID cisplatin partially clears the mammary epithelium. In conclusion, we propose that ID chemotherapy treatment may be used as a prophylactic ablation agent to prevent development of hereditary breast cancer.

P13

Increased Expression of Phosphorylated mTOR in Metastatic Breast Tumors Compared to Primary Tumors in Patients Who Received Adjuvant Endocrine Therapy

K Beelen¹; © LDC Hoefnagel²; M Opdam¹; J Wesseling¹; PJ van Diest²; S Linn¹

¹NKI-AVL, Amsterdam, Netherlands; ²UMC Utrecht, Utrecht, Netherlands

Activation of the PI3K pathway as an adaptive change in response to estrogen depletion results in acquired endocrine therapy resistance in vitro. Metastatic breast cancer patients with previous exposure to endocrine therapy derive substantial benefit from the addition of an mTOR inhibitor to endocrine therapy compared to endocrine therapy alone. This suggests that compensatory PI3K pathway activation might play a role in the development of clinical resistance to endocrine therapy. We evaluated the activation of the downstream PI3K pathway protein mTOR in primary breast tumors and corresponding metastases. From a previously described series of metastatic breast cancer patients, we selected ERα positive patients who had received endocrine therapy (N=34) and who did not receive endocrine therapy (N=37). The difference in expression of p-mTOR between primary and metastatic tumour was assessed by IHC, which was scored using the proportion of tumour cells with sub-membranous p-mTOR expression. We assessed whether this difference was associated with clinico-pathological factors or varied between patients who did and did not receive endocrine therapy. In patients who had received endocrine therapy we observed an increase in p-mTOR expression in metastatic tumour lesions compared to the primary tumour (mean difference 40%). This was significantly different from the increase observed in patients who did not receive endocrine therapy (mean difference 6 %) (p=0.003). The difference remained significant in the multivariate regression model. In patients who received previous adjuvant endocrine therapy, the increase in p-mTOR expression in metastatic tumour lesions compared to the primary tumour is significantly higher than patients who did not receive endocrine therapy. Compensatory activation of the PI3K pathway might therefore be a clinically relevant resistance mechanism resulting in secondary endocrine therapy resistance.

P14

A Case Report Highlighting the Diagnostic Difficulty of Granular Cell Tumour of the Breast.

© A Vargiamidou¹; Y Maurice¹; A Clark¹; D Killeen²; M Holland²; S Poonawala³

¹Arrowe Park Hospital, Upton, United Kingdom; ²Clatterbridge Hospital, Bebington, United Kingdom; ³Wirral University Teaching Hospital, Upton, United Kingdom

Granular cell tumours are rare tumours arising from Schwann cells of peripheral nerves. Approximately 5 to 15% of all granular cell tumours arise in the breast. The tumour most commonly presents in premenopausal woman and can arise anywhere in the breast parenchyma, axillary tail or subcutaneous tissue. The tumour most frequently occurs in the inner quadrant corresponding to the supraclavicular nerve distribution. Clinically, it can present as a firm, painless mass with elastic consistency which may or may not be fixed to the underlying muscle wall.

Radiological presentation of the tumour is variable. It can present as an irregular, spiculate stellate mass with no associated calcifications in a mammogram. Ultrasound and dynamic MR mammography presentations can be equally misleading. Histologically the tumour consists of solid nests of polygonal or spindle cells with abundant eosinophilic granular cytoplasm, prominent nucleoli and moderate cellular atypia.

Immunohistochemically the tumour is positive for S100 given its Schwann cell origin. as well as CD68 positive. The tumour is negative for cytokeratins, MelanA and HMB45.

Case Presentation: A 53 year old was invited for further imaging and evaluation of a suspicious mass in her left breast. Further radiological investigations pointed to a malignant diagnosis (U5 M5). Core biopsy of the lesion identified a granular cell tumour of the breast.

Conclusion: Granular cell tumours of the breast are rare tumours that can easily be mistaken for malignancy clinically and radiologically. This case highlights the diagnostic difficulty of granular cell tumour of the breast.

P15

Is there a Correlation Between Margin of Clearance and Recurrence Rate in Patients with DCIS (Ductal carcinoma in situ)?

© AS Azam¹; AH Youssef¹; SB Absar²

¹Russells Hall Hospital, Dudley Group NHS Foundation Trust, Dudley, United Kingdom; ²Dudley Group NHS Foundation Trust, United Kingdom

Background:

Breast Cancer is the most common cancer for women in England and Wales, with about 40,500 new cases diagnosed and 10,900 deaths recorded each year. Early breast cancer is subdivided into two major categories, in situ disease, mainly in the form of ductal carcinoma in situ (DCIS), and invasive cancer. DCIS accounts for 20% of screen detected cancers in the United Kingdom.

Objectives: To see "Is there a correlation between excision margins and recurrence rate in patients who underwent WLE(wide local excision) for DCIS?

Standard: NICE guidelines state that "For all patients treated with breast conserving surgery for DCIS a minimum of 2 mm radial margin of excision is recommended with pathological examination to NHSBSP reporting standards. Re-excision should be considered if the margin is less than 2 mm, after discussion of the risks and benefits with the patient"

Target: 100%

Methodology:A retrospective study including patients who underwent WLE for DCIS over the period of three years (From 2005-2007).

Results:A total of 21 patients were identified who underwent WLE for DCIS. 8 patients were excluded as their biopsy report showed invasive component. A total of 11 patient's case notes were analyzed. All 11 patients were female with a mean age of 62 years (Range 50-92). The average size of the lesion was 11mm (Range 3-28mm) in these patients. The average excision margin was 9.3mm(2-16mm) in 9 out of 11patients. None of the patients had recurrence of DCIS or invasive cancer after being followed up for five years.

Conclusion:Our results show that there was no recurrence in all our patients. However, we have seen a wide range of margins of clearance (2-16mm). In our trust the current practice shows that a large number of these patients had the excision margin of 10mm or above. We believe we should develop local trust guidelines to have a more standardized approach as a trust or just follow NICE guidelines.

P16

An Unusual Variant of Metaplastic Mammary Carcinoma, Pseudoangiosarcomatous / Acantholytic Variant.

© YMM Maurice; U Azhar; KS Kamla Sidky

Wirral University Teaching Hospital NHS Trust, Wirral, United Kingdom

This is an unusual variant of metaplastic carcinoma of breast. Only sporadic cases have come to light since this entity was defined in 1986. The acantholytic variant of squamous cell carcinoma is characterized by the formation of irregular spaces lined by atypical squamous cells leading to a pseudoglandular or pseudoangiosarcomatous appearance. It should be considered as a potential differential diagnosis with angiosarcoma.

We present a case of acantholytic/pseudoangiosarcomatous carcinoma of the breast in a 65 year old lady who presented with a palpable mass in her left breast. A core biopsy demonstrated a malignant neoplasm composed of anastomosing channels lined by spindle shaped cells in a densely collagenous stroma with focal myxoid areas. The diagnosis was made after immunohistochemistry demonstrated the epithelial nature of the neoplasm and endothelial markers were negative. Immunohistochemical analysis of metaplastic carcinomas has revealed that >90% of these cancers are negative for ER, PR and HER2, and express keratins CK5/6 and 14, and EGFR.

Awareness and subsequent recognition of this specific variant of metaplastic carcinoma is important to prevent misdiagnosis and allow proper treatment.

P17

Audit of Fine Needle Aspiration Cytology of Breast Lesions.

© AVM Speller; C Craig

St Mary's Hospital, Imperial College Healthcare NHS Trust, London, United Kingdom

Background: NICE states that patients with breast lesions should undergo 'triple assessment' the three parts of this being: history and clinical examination, imaging, and needle core biopsy (NCB) or fine needle aspiration cytology (FNAC). At our centre both are performed.

Aims & Objectives: We want to assess whether we are meeting the minimum thresholds set out in the European guidelines. We will compare the sensitivity, specificity and other indicators of our procedure, to the minimum threshold figures given in the guidelines.

Standards: Minimum thresholds as set out by the European guidelines for quality assurance in breast cancer screening and diagnosis. Fourth Edition.

Method: Data on all FNAC of breast lesions carried out in 2010 and 2011 was reviewed. We recorded the results of the FNAC along with any histology and B code. The cytology opinion was compared to any histology.

The histology result from the most definitive procedure was used, i.e. if the patient had had both a NCB and a wide local excision, the histology result from the wide local excision specimen was used. Any histology that did not have a B code assigned was given one by us, following the specifications given in the guidelines.

Results: We meet the majority of the thresholds given in the guidelines. Measures for improvement are discussed.

P18

Differences in FGF1 and FGFR2 Expression in BRCA1-associated, BRCA2-associated, and Sporadic Breast Carcinomas.

© S Vos; E van der Wall; PJ van Diest; P van der Groep

UMC Utrecht, Utrecht, Netherlands

Introduction. Contrasting to BRCA1-related breast cancer, a distinctive phenotype for BRCA2-related carcinomas has not been found yet as there is no clear distinction between BRCA2 and sporadic tumours. Recently, studies suggest overexpression of fibroblast growth factor 1 (FGF1) and fibroblast growth factor receptor 2 (FGFR2) in BRCA2 tumours. This study aims to investigate whether there is indeed FGF1 and/or FGFR2 protein overexpression in BRCA2 carcinomas in comparison to BRCA1 and sporadic tumours. This would reveal the usefulness of FGF1 and FGFR2 immunohistochemistry in daily pathological practise.

Method. Invasive breast carcinomas of 33 BRCA1 and 22 BRCA2 germline mutation carriers and a tissue microarray containing 104 sporadic invasive breast carcinomas were immunohistochemically stained for FGF1, FGFR2, and to assess molecular phenotype: estrogen receptor (ER), progesterone receptor (PR), HER2, epidermal growth factor receptor 1 (EGFR), cytokeratin (CK) 5/6, and CK14.

Results. FGFR2 expression was seen in 68.2% and 79.0% of BRCA2 and sporadic carcinomas respectively, in contrast to 22.6% of BRCA1 tumours ($p = 0.000$). FGFR2 expression was seen in 88.9% of luminal A type carcinomas and 17.1% of basal-like carcinomas ($p = 0.000$). FGF1 was expressed by 72.7% of BRCA2 carcinomas and 45.2% and 41.8% in BRCA1 and sporadic carcinomas, respectively ($p = 0.032$).

Conclusion. FGFR2 expression differs significantly between BRCA1 and BRCA2 breast carcinomas and between cancers of luminal A and basal phenotype, but not between BRCA2 and sporadic cancers. FGF1 expression differs significantly between BRCA2 and sporadic carcinomas and could be used as a BRCA2-specific biomarker.

P19

MMP-8 Loss Contributes to Altered Myoepithelial Cell Function in DCIS

© M Sarper¹; MD Allen¹; J Decock²; S Thirkettle²; DR Edwards²; JF Marshall¹; LJ Jones¹

¹Barts Cancer Institute, London, United Kingdom; ²University of East Anglia, Norwich, United Kingdom

Matrix metalloproteinase-8 (MMP-8) is a member of the MMP family, key enzymes involved in remodelling extracellular matrix (ECM), with a known role in cancer cell invasion. In normal breast MMP-8 is secreted predominantly from myoepithelial cells (MECs), which show a distinct tumour suppressor phenotype. In ductal carcinoma in situ (DCIS), MECs lose MMP-8, over-express $\alpha v \beta 6$ integrin and show a gradual loss of suppressor activity. Our aims are to establish the link between MMP-8 loss and $\alpha v \beta 6$ up-regulation, and determine whether loss of MMP-8 expression in DCIS contributes to loss of tumour suppressor activity and contributes to invasion.

Primary normal MECs expressed MMP-8 and this expression was lost in DCIS associated counterparts. An inverse correlation was demonstrated between $\alpha v \beta 6$ and MMP-8 in an $\alpha v \beta 6$ over-expressed DCIS MEC model (Myo- $\beta 6$). When MMP-8 was re-introduced to Myo- $\beta 6$, the wild type (wt) but not inactive MMP-8, significantly up-regulated the MEC adhesion to ECM, but, contradictorily reduced MEC migration towards ECM. In addition leading edge filopodial protrusions were significantly shorter in MMP-8wt compared to control group.

To analyse the paracrine effect of MMP-8 on breast cancer cell invasion, modified Myo- $\beta 6$ were co-cultured with MDA MB 231 or SUM159PT cells in 3D DCIS related stromal microecology recapitulative organotypic models. A significant reduction in breast cancer cell invasion was observed solely when co-culturing with MMP-8wt. Therefore these results suggest that MMP-8 does contribute to MEC tumour suppressor function, dependent on its enzymatic activity. In the future the suppressor mechanism will be further dissected by investigating TGF- β downstream signalling, $\beta 1$ integrin interaction and a series of DCIS samples with known outcome will be screened for MMP-8 mRNA expression by in situ hybridization.

P20

EGFR Mutation Analysis Is Feasible in Sputum Samples of Lung Cancer Patients

© AJ Hubers¹; DAM Heideman¹; Y Yatabe²; MD Wood³; J Tull³; M Tarón⁴; GJM Herder⁵; R Koning¹; GA Meijer¹; PJF Snijders¹; BI Witte⁶; PE Postmus⁷; EF Smit⁷; E Thunnissen¹

¹VU University Medical Center/Department of Pathology, Amsterdam, Netherlands; ²Aichi Cancer Center Hospital/Departments of Pathology and Molecular Diagnostics, Nagoya, Japan; ³University Hospital of Wales/Institute of Medical Genetics, Cardiff, Wales, United Kingdom; ⁴Hospital Germans Trias i Pujol/Catalan Institute of Oncology; USP Dexeus University Institute-PangaeaBiotech, Badalona, Catalonia, Spain; ⁵Sint Antonius Hospital/Department of Pulmonary Diseases, Nieuwegein, Netherlands; ⁶VU University Medical Center/Department of Epidemiology and Biostatistics, Amsterdam, Netherlands; ⁷VU University Medical Center/Department of Pulmonary Diseases, Amsterdam, Netherlands

Purpose of the study: Mutations in the tyrosine kinase domain of the epidermal growth factor receptor (EGFR) have been identified in lung cancer adenocarcinomas and are associated with high response chance to EGFR tyrosine kinase inhibitors in the treatment of lung cancer. EGFR mutations can be detected in tumour tissue, cytology specimens and blood from lung cancer patients. Thus far, EGFR mutation analysis has not been demonstrated for sputum samples in a systematically conducted study. The aim of the present study was to determine whether EGFR mutation analysis is attainable on sputum samples, employing different assays in a multicentre study.

Methods: Sputum from 10 lung cancer patients with confirmed EGFR mutation in their tumour tissue, 10 lung cancer patients without evidence of an EGFR mutation, and 10 patients with chronic obstructive pulmonary disease (COPD) was used for mutation analysis. EGFR mutation status of tumour tissue was assessed by High Resolution Melting followed by sequencing (HRM-sequencing). DNA aliquots of sputum specimens were shipped to the collaborating laboratories for EGFR mutation analysis by Cycleave PCR, COLD-PCR and PangaeaBiotech SL technology (PST), respectively. Additionally, at the central laboratory, sputum DNAs were subjected to HRM-sequencing to confirm mutations.

Results: Dependent on the assay, EGFR mutations could be detected in 30% to 50% of the sputum samples of patients with EGFR mutations detected in their tumour tissue specimen. The different techniques revealed consistent results, with slightly higher sensitivity for PST. Neither the lung cancer patients without EGFR mutation in their tumour nor the COPD controls tested positive for EGFR mutations in their sputum samples, indicating high clinical specificity of all assays.

Conclusion: EGFR mutations can be detected in sputum samples from patients with EGFR-mutated non-small cell lung cancer with various techniques.

P21

Multi Drug Resistance Protein BCRP Protects Adipose Derived Stem Cells Against Ischemic Damage

© BA Naaijken; A van Dijk; WFM Jurgens; R Oerlemans; GL Scheffers; AC van Rossum; GJ Schuurhuis; FJ van Milligen; HWM Niessen

VUMC, Amsterdam, Netherlands

Adipose derived stem cells (ASC) are promising candidates for cellular therapy, for instance after myocardial infarction. However, when transplanted in the infarcted heart, ASC are jeopardized by an ischemic environment, leading to cell death of the administered cells. Efflux of harmful substances performed by multi drug resistance (MDR) proteins is a well known characteristic of stem cells. Several MDR proteins have been identified on different types of stem cells, however, not much research to investigate the expression and functional activity of the MDR proteins breast cancer resistance protein (BCRP) and P-glycoprotein (P-GP) in ASC, in normal and ischemic conditions. BCRP and P-GP expression was analyzed over culture (passage 2 to 6) by western blot analysis showing expression of BCRP, but not of P-GP. Interestingly, BCRP expression was most prominent in early passages and decreased during culture. Furthermore, immunohistochemical analysis showed BCRP expression on the nucleus, but not on the cell surface membrane. Using a specific substrate extrusion assay functional activity of BCRP was shown. Moreover, we showed that ischemia induced protein expression of BCRP in the nucleus and cytoplasm. Finally, using flow cytometry we determined that blockage of BCRP results in significantly more cell death during ischemia. In conclusion, 1) ASC express BCRP, which decreases during culture. 2) BCRP expression increases in ischemic conditions, and 3) BCRP protects ASC from cell death in an ischemic environment. Therefore, cellular therapy during ischemia is optimal using low passage ASC when expression of BCRP is high.

P22

Monocyte Subset Accumulation in the Human Heart Following Acute Myocardial Infarction and the Role of the Spleen as Monocyte Reservoir

© EN ter Horst¹; AM van der Laan¹; MPV Begieneman²; A Hirsch¹; PAJ Krijnen²; M Nahrendorf³; AJ Horrevoets²; HWM Niessen²; JJ Piek¹

¹Academic Medical Center, Amsterdam, Netherlands; ²VU University Medical Center, Amsterdam, Netherlands; ³Massachusetts General Hospital, Boston, United States

Aims Monocytes are critical mediators of healing following acute myocardial infarction (AMI), making them an interesting target to improve myocardial repair. The purpose of this study was gain insight into the source and recruitment of monocytes following AMI in humans.

Methods and results Post-mortem tissue specimens of myocardium, spleen and bone marrow were collected from 28 patients that died at different time points after AMI. Twelve patients that died from other causes served as controls. Presence and localization of monocytes (CD14+ cells), and their CD14+CD16- and CD14+CD16+ subsets were evaluated by immunohistochemical and immunofluorescence analyses. CD14+ cells localized at distinct myocardial areas following AMI. At 12 h-5 days after AMI, CD14+ cells were predominantly located in the infarct border zone, adjacent to cardiomyocytes, and consisted for 85% [78-92] of CD14+CD16- cells. In contrast, 5-14 days after AMI, massive accumulation of CD14+ cells was observed in the infarct core, containing comparable proportions of the CD14+CD16- subset (60% [31-67]) and the CD14+CD16+ subset (40% [33-69]). Importantly, in patients with AMI, of the number of CD14+ cells was decreased by 39% in the bone marrow and by 58% in the spleen, in comparison to control patients (P=0.02 and P<0.001, respectively).

Conclusions Overall, this study showed a unique spatio-temporal pattern of monocyte accumulation in the human myocardium following AMI that coincides with a marked depletion of monocytes from the spleen, suggesting that the human spleen contains an important reservoir function for monocytes.

P23

Two Young Women with a Soft Tissue Tumour of the Heart

© SI Lok¹; MEI Schipper¹; JWJ Hinrichs¹; JC Post²; IO Baas³; RA Weger¹; N de Jonge¹

¹UMC Utrecht, Utrecht, Netherlands; ²Catarina Ziekenhuis, Eindhoven, Netherlands; ³Meander Medisch Centrum, Amersfoort, Netherlands

Introduction: Primary malignant neoplasms of the heart are exceptionally rare, mostly of vascular origin and classified as angiosarcomas. The overall survival of patients with a soft tissue sarcoma of the heart is poor, irrespective of histopathology, grading and staging. Case reports: Patient 1 (female, 19 years) presented with ventricular tachycardia, caused by an intracardiac tumour. Incisional biopsy showed a sarcoma, not otherwise specified without distant metastases. Because local radical resection was impossible, she underwent HTx 4 months later. The explanted heart showed a radically removed malignant mesenchymal tumour of max. 7.5 cm with multiple satellite lesions and central cystic degeneration. Histopathology displayed a sarcoma NOS with moderate cellular atypia and low mitotic activity. Four years later she is doing well under immunosuppressive therapy without local recurrence or distant metastases. Patient 2 (female, 26 years) presented with a vena cava superior syndrome, caused by a tumour of the right atrium. Incisional biopsy displayed a Kaposiform haemangio-endothelioma. HHV-8 and HIV-status were negative. Local VCS obstruction made immediate surgical intervention necessary. A complete resection of the right atrium was performed, followed by reconstruction with a bovine patch. Histopathology showed an irradically removed haemangio-endotheliosarcoma of at least 9.0 cm with vaso-invasive growth. In the 6th postoperative week extensive systemic metastases were diagnosed. Despite second-line chemotherapy her clinical condition deteriorated and she died 4 months later.

Summary: Decision making is challenging in health care of young patients with a difficult to diagnose and treat soft tissue sarcoma of the heart. An extensive process of interdisciplinary discussions and ethical considerations is necessary to avoid mistreatment and unreal expectations. However, frequently the clinical outcome is unexpected.

P24

Cardiac Allograft Vasculopathy: a Quantitative Analysis of Changes in Coronary Artery Wall Architecture after Heart Transplantation

© MMH Huibers¹; J Kaldewey¹; A Huisman²; HFJ Dullens¹; MEI Schipper¹; N De Jonge¹; RA De Weger¹

¹University Medical Centre Utrecht, Utrecht, Netherlands; ²MedicalPHIT, Utrecht, Netherlands

Background: Long term survival after heart transplantation (HTx) is hampered by chronic rejection. A critical step in this process is the immune reaction directed to the donor coronary arteries, leading to Cardiac Allograft Vasculopathy (CAV). The mononuclear cell (MNC) infiltration in the neo-intima (NI) of the vessel leads to progressive NI thickening and luminal narrowing. Aim: To quantitatively investigate the relation between artery wall architecture and duration of survival after HTx.

Methods: Three or more arterial cross sections were available after autopsy of 30 HTx patients. The surface area of the different vessel layers was measured microscopically using Aperio ImageScope. To distinguish the layers in the arterial wall, sections were stained with Haematoxylin eosin, Elastica von Gieson and Smooth muscle cell (SMC) actin.

Results: Survival after HTx did not exceed 10 years in all but one patient. From 2 weeks upward infiltration of MNC was detected. Up to 3 years after HTx NI proliferation and luminal narrowing was observed (both p<0.05). In the 10 year period these relations disappeared and only thinning of the media was observed (p<0.05). CAV can be classified in 4 stages: Stage 1 is a normal coronary artery. During stages 2-4 CAV developed and an additional layer (NI-LL) between the endothelium and NI-SMC layer is formed. Some cases showed total luminal occlusion, which can be observed at all CAV stages.

Conclusions: CAV is an ongoing process with increasing fibrosis of the NI. In the first few years after transplantation MNC infiltration, NI proliferation and luminal narrowing is found. Unexpectedly after this period the media progressively gets thinner, but the NI does not increase, nor does the lumen reduce. The NI seems to solidify into solid fibrous tissue with presumably loss of contractility and elasticity, but due to outward remodelling the diameter of the lumen remains uncompromised.

P25

The Composition of Macrophages in Extravascular Infiltration after Heart Transplantation

© MMH Huibers; H Feringa; R Kruit; A Vink; ALM Peeters; N De Jonge; RA De Weger

University Medical Centre Utrecht, Utrecht, Netherlands

Background: In heart transplantation (HTx) chronic immune rejection still hampers longterm survival. Hyperplasia of the neointima in coronary arteries, cardiac allograft vasculopathy (CAV), is part of this process. The role of extravascular infiltration areas (EIA) in this chronic immune rejection is not elucidated yet. These characteristic areas are located in the adipose tissue or myocardium of the heart. A small pilot indicated that a part of the immune cells in those areas are macrophages.

Aim: Determine the composition of macrophages in the extravascular infiltration areas after heart transplantation.

Methods: In twenty-two patients the composition and distribution of the different (sub) types of macrophages was studied in EIAs with immunohistochemistry. The composition of macrophages was also analyzed in several parts of the heart tissue; the coronary vessel wall, adipose tissue and myocardium. All slides were semi-quantitatively scored for positive staining and expressed as percentage of total amount mononuclear cells. The amount of macrophages was related to the extent of the chronic immune rejection and H-CAV stage.

Results: In most areas a significant higher percentage of M2 macrophages were detected compared to M1 macrophages. The composition of macrophages was comparable in the different areas. Most macrophages are located in the intimal layer of the vessel wall. The amount of macrophages was related to the extent of the chronic immune rejection, this appeared not to be significant. Besides, the amount of macrophages between the different H-CAV stages was not significantly different.

Conclusions: The EIAs are composed of mainly lymphocytes with an equal number of B- and T-cells. In contrast to the neo-intima infiltration, which is mainly composed of T-cells. Overall the macrophages in the EIAs (about 10%) were anti-inflammatory M2 macrophages, suggesting a Th2-response resulting in a humoral reaction.

P26

Common Genetic Aberrations Observed in Left-Sided Colorectal Tumours are Influenced by Diet and Lifestyle

© LJ Gay¹; A Naguib¹; J Keen¹; J Cooke¹; JY Park²; R Bowman¹; GG Kuhnle³; PA Burns⁴; R Luben⁵; A McTaggart²; M Lentjes²; KT Khaw⁵; RY Ball⁶; AEK Ibrahim⁷; PN Mitrou²; MJ Arends⁷

¹MRC Dunn Human Nutrition Unit, Cambridge, United Kingdom;

²MRC Centre for Nutritional Epidemiology in Cancer Prevention and Survival, Cambridge, United Kingdom; ³Department of Food & Nutritional Sciences, University of Reading, Reading, United Kingdom; ⁴Leeds Institute of Molecular Medicine, St James's University Hospital, Leeds, United Kingdom; ⁵Department of Public Health and Primary Care, University of Cambridge, Cambridge, United Kingdom; ⁶Norfolk and Waveney Cellular Pathology Network, Norfolk and Norwich University Hospital, Norwich, United Kingdom; ⁷Department of Pathology, University of Cambridge, Cambridge, United Kingdom

Genetic aberrations occurring commonly in colorectal cancer (CRC) include mutations in *APC*, *KRAS* and *TP53* and hypermethylation at *APC* promoter 1A. These are associated with the chromosomal instability (CIN) pathway of CRC development, which may be influenced by dietary and lifestyle risk factors for CRC.

G-to-A mutations in *APC* in CRC have been associated with increased processed meat consumption, whereas microsatellite instability, an alternative pathway of CRC development, is not influenced by diet and lifestyle. Here, mutations in the *APC* mutation cluster region (codons 1276-1556), *TP53* exons 5-8, *KRAS* exons 1-2 and methylation of *APC* promoter 1A were examined together in 185 archival CRCs from the European Prospective Investigation of Cancer (EPIC)-Norfolk Study, for whom lifestyle and dietary data had been collected in the form of seven-day diaries. 75% of CRCs had at least one genetic aberration in *APC*, *KRAS* or *TP53* (Mut+). Mut+ cases were associated with increased pack-years of smoking ($P = 0.002$) and higher consumption of processed meat than Mut- cases ($P = 0.007$). However, cases with Mut+ tumours located in the distal colon or rectum smoked for ten pack years more than those with Mut- tumours in the distal bowel ($P < 0.001$) and they consumed more alcohol and processed meat ($P = 0.03$ and 0.001). A logistic regression model adjusted for sex and age at diagnosis supported these findings; OR 2.24, 95% CI 1.19-4.20 and OR 4.08, 95% CI 1.26-13.17 for each 1SD increase in processed meat and pack years of smoking, respectively.

In conclusion, diet and lifestyle appear to influence CRC development via the CIN pathway. Smoking and processed meat consumption have greater effects on CIN+ CRCs in the distal colon or rectum, consistent with exposure to *N*-nitroso compounds.

P27

Cytotoxic Lymphocyte Granzyme M Targets Host Cell Protein hnRNP K That is Essential for Human Cytomegalovirus Replication

R van Domselaar¹; SAH de Poot¹; EBM Remmerswaal²; KW Lai¹; IJM ten Berge²; © N Bovenschen¹

¹University Medical Center Utrecht, Utrecht, Netherlands; ²Academic Medical Center Amsterdam, Amsterdam, Netherlands

Human cytomegalovirus (HCMV) is the most frequent viral cause of congenital defects and HCMV infection in immunocompromised patients may trigger devastating disease. Cytotoxic lymphocytes control HCMV by releasing granzymes towards virus-infected cells. In mice, granzyme M (GrM) plays a physiological role in controlling murine CMV infection. However, the underlying mechanism remains poorly understood. In the present study, we showed that human GrM was expressed by HCMV-specific CD8+ T cells both in latently-infected healthy individuals and in transplant patients during primary HCMV infection. We identified host cell heterogeneous nuclear ribonucleoprotein K (hnRNP K) as a physiological GrM substrate. GrM most efficiently cleaved hnRNP K in the presence of RNA at multiple sites, thereby likely destroying hnRNP K function. Host cell hnRNP K was essential for HCMV replication not only by promoting viability of HCMV-infected cells but predominantly by regulating viral immediate-early 2 (IE2) protein levels. Furthermore, hnRNP K interacted with IE2 mRNA. Finally, GrM decreased IE2 protein expression in HCMV-infected cells. Our data suggest that targeting of hnRNP K by GrM contributes to the mechanism by which cytotoxic lymphocytes inhibit HCMV replication. This is the first evidence that cytotoxic lymphocytes target host cell proteins to control HCMV infections. (Cell Death and Differentiation. 2012; In Press)

P28

Chromosomal Aberrations Implicated in Colorectal Adenoma to Carcinoma Progression as Markers of High Risk Colorectal Adenomas

© B Diosdado¹; JS Terhaar sive Droste²; A Bolijn¹; MK van Burink¹; NCT van Grieken¹; B Carvalho¹; CJJ Mulder²; GA Meijer¹

¹Department of Pathology, VU Medical Center, Amsterdam, Netherlands; ²Department of Gastroenterology and Hepatology, VU Medical Center, Amsterdam, Netherlands

Purpose of the study: Advanced adenomas are considered as an intermediate endpoint for colorectal cancer (CRC) screening. Still the majority of these lesions do not progress to cancer. Hence, using this intermediate endpoint in evaluation of screening programs may lead to an overestimation of the effect of screening. Underlying genomic alterations like chromosomal instability characteristic of colorectal adenoma to carcinoma progression (gains of 8q, 13q, 20q and losses of 8p, 15q, 18q) may more precisely mark high risk adenomas. Previously, we have shown that the presence of two or more of these particular chromosomal alterations was associated with malignant progression. The aim of this study is to evaluate the prevalence of chromosomal aberrations implicated in colorectal adenoma to carcinoma progression in advanced and non-advanced colorectal adenomas. Methods: The prevalence of DNA copy number gains and losses of 8q, 13q, 15q, 18q, 20q, 8p and 17p was determined in 65 advanced and 58 non-advanced adenomas using multiplex ligation-dependent probe amplification (MLPA). Adenomas >1.0 cm, with any villous features (i.e. tubulovillous or villous adenoma) or high-grade dysplasia were called advanced adenomas, while tubular adenomas, <1.0 cm and with low-grade dysplasia were called non-advanced adenomas.

Summary of the results: 22% of advanced adenomas showed two or more cancer associated chromosomal aberrations compared to 2% in the non-advanced adenomas. DNA copy number gain of 20q was the most frequent chromosomal aberration found in 12.2% of the adenomas. DNA copy number gains occurred more frequently than losses. Presence of 13q and 20q gains were significantly more present in adenomas >1.0 cm than <1.0 cm ($p=0.01$ and $p=0.001$ respectively). 8q gain and 17p loss were significantly more present in adenomas with high degree dysplasia than with low degree dysplasia ($p=0.04$ and $p=0.01$ respectively). None of the DNA copy number changes studied was associated with the histological subtypes of advanced adenomas.

Conclusions: 22% of the advanced adenomas and 2% of the non-advanced adenomas showed two or more CRC associated chromosomal aberrations. These findings are consistent with the hypothesis that the morphological parameters used to classify adenomas lack specificity as an intermediate endpoint in colorectal cancer screening.

P29

All Human Granzymes Target hnRNP K That is Essential for Tumour Cell Viability.

R van Domselaar; R Quadir; AM van der Made; R Broekhuizen;
© N Bovenschen

University Medical Center Utrecht, Utrecht, Netherlands

Granule exocytosis by cytotoxic lymphocytes is the key mechanism to eliminate virus-infected cells and tumour cells. These lytic granules contain the pore-forming protein perforin and a set of five serine proteases called granzymes. All human granzymes display distinct substrate specificities and induce cell death by cleaving critical intracellular death substrates. In the present study, we show that all human granzymes directly cleaved the DNA/RNA-binding protein heterogeneous nuclear ribonucleoprotein K (hnRNP K), designating hnRNP K as the first known pan-granzyme substrate. Cleavage of hnRNP K was more efficient in the presence of RNA and occurred in two apparent proteolysis-sensitive amino acid regions, thereby dissecting the functional DNA/RNA-binding hnRNP K domains. HnRNP K was cleaved under physiological conditions when purified granzymes were delivered into living tumour cells and during lymphokine-activated killer cell-mediated attack. HnRNP K is essential for tumour cell viability, since knockdown of hnRNP K resulted in spontaneous tumour cell apoptosis with caspase activation and reactive oxygen species production. This apoptosis was more pronounced at low tumour cell density where hnRNP K knockdown also triggered a caspase-independent apoptotic pathway. This suggests that hnRNP K promotes tumour cell survival in the absence of cell-cell contact. Silencing of hnRNP K protein expression rendered tumour cells more susceptible to cellular cytotoxicity. We conclude that hnRNP K is indispensable for tumour cell viability and our data suggest that targeting of hnRNP K by granzymes contributes to or reinforces the cell death mechanisms by which cytotoxic lymphocytes eliminate tumour cells. (J Biol Chem. 2012; 287:22854-64).

P30

Cten Localisation and its Impact on Cancer Metastasis

© S AlGhamdi; M Akhlaq; D Jackson; M Ilyas

University of Nottingham, Nottingham, United Kingdom

Cten is a member of the tensin gene family and we have previously shown that it acts as an oncogene in colorectal, pancreatic and lung cancer. The Cten protein is classically located at focal adhesions and has a role in regulating cell motility. However, by immunohistochemistry, we observed the presence of Cten within the nucleus of colorectal tumours and found that high nuclear expression correlated with metastasis. In order to investigate this further, we tested for nuclear Cten expression cell lines derived from colorectal, pancreatic and lung tumours. Cten was detectable by Western blotting in the nuclear protein fraction of all three tumour types. Unexpectedly, the proportion of nuclear Cten was higher in lung cancer cell lines than in colonic or pancreatic cancer cell lines. Furthermore, in the lung cancer cell lines, modulation of Cten levels (by forced expression and gene knockdown) altered cell proliferation whilst in colorectal and pancreatic cell lines, the effect was not seen in colorectal or pancreatic cell lines. In order to activity of Cten in the nucleus, we aimed to target Cten specifically to the nucleus using a nuclear localisation signal (NLS)-tagged Cten (NLS-Cten). The NLS-Cten construct was forcibly expressed in two colorectal cancer cell lines (HCT116 and RKO, both low expressers of Cten). This resulted in increased migration (by transwell and wound healing assay) compared to both empty vector controls and the usual Cten expression vectors. We conclude that Cten may stimulate cell motility through both unlinking focal adhesions from the actin cytoskeleton and from as yet undetermined activity in the nucleus.

P31

Exon 9b Inclusion In CHRFA7A and Nicotinic Acetylcholine Receptor (CHRNA7) Genes: The Effect of Single Nucleotide Substitution

© O Ahmad; T Guetta-Baranas; N Kalsheker; S Chappell

University of Nottingham, Nottingham, United Kingdom

Background: CHRNA7 and CHRFA7A genes regulate the expression of alpha-7 nicotinic acetylcholine receptor. This protein plays a major part in cholinergic anti-inflammatory pathway via suppressing inflammation and keeping it localized. Alternative RNA splicing is a crucial process that results in multiple RNA transcripts and affects about 50% of all human genes. The change in certain sequence motifs within a gene can affect the exons included in the subsequent mRNA, thus predisposing to alternative transcripts. This effect can be attributed to nucleotide changes at exon splice enhancers (ESE). Such a change can affect the subsequent protein translation, ending in a protein with no or alternative function.

The aim of the present study was to test for the effect of single nucleotide differences on splicing between two duplicated genes, CHRNA7 and CHRFA7A predicted to result in alternative transcripts.

Methods: The sequence of two genes, CHRNA7 and CHRFA7A, was compared from NCBI database. DNA fragments corresponding to the single base differences were generated using minigenes and site-directed mutagenesis techniques. Then DNA fragments were transfected into A549 and Cos7 cells.

Then mRNA transcripts were detected for alternative splicing using RT-PCR. Results: The expression of a transcript that contains an additional exon (9b) was shown to be affected by single base difference between both genes. This base was detected earlier to be located at an ESE site using RESCUE-ESE software.

Conclusion: a single base (C) can enhance the inclusion of exon (9b) in CHRFA7A rather than CHRNA7 transcripts. This base is located at ESE site which seems to be strengthened when this base is C rather than G. CHRFA7A was confirmed to control CHRNA7 and alpha7-protein expression. This might be mediated via expression of intermediate mRNA transcripts, such as one with exon (9b) that could play a role in the negative feedback mechanism.

P32

A Next Generation Sequencing Approach to Mutation Detection in Normal Mucosa

© KM Sutton; SD Richman; GR Taylor; P Quirke

Leeds Institute of Molecular Medicine, Leeds, United Kingdom

KRAS codon 12 and 13 mutations have previously been reported in morphologically normal mucosa through PCR-based detection techniques. These mutations occur at very low frequency, requiring a highly sensitive technique for detection. The use of targeted sequencing with high throughput next generation sequencing (NGS) allows for very high sensitivity mutation detection in multiple samples. We used NGS to test morphologically normal colorectal mucosa from 38 patients that had mutated KRAS codon12/13 tumours. DNA from 38 formalin fixed paraffin embedded (FFPE) normal mucosa samples was extracted and amplified by PCR for KRAS codons 12&13. The matched tumour samples had a previously confirmed KRAS codon 12/13 mutation by pyrosequencing. Samples of normal then underwent NGS library preparation and were barcoded to be multiplexed. Reads were then bioinformatically processed to de-multiplex and filter on quality before they were aligned to a reference sequence and analysed for mutations in codons 12&13. We reproducibly detected mutations in 6 of the normal mucosa samples (16%) with the mutated allele frequency ranging from 1% - 10.5%. The pattern of KRAS codon 12 & 13 mutations occurring in the normal samples matched that which is reported for KRAS in CRC. We further confirmed the KRAS 12/13 mutations in the tumour samples by NGS. We have identified that mutations occur in the normal mucosa without morphological lesions. Therefore activation of the KRAS oncogene alone can precede morphological lesions. It may however, be usable as an indicator of genetic damage in the bowel due to exposure of carcinogens and have potential use as a screening tool to identify those who have a higher CRC risk. We have also demonstrated that NGS is an accurate and sensitive technique for the detection of low level mutations in multiplexed samples.

P33

Molecular Diagnostics of a Multifocal Non Small Cell Lung Cancer Case Using Targeted Next Generation Sequencing

© WRR Geurts-Giele¹; AW Dirckx-van der Velden²; NMM Bartalits²; LC Verhoog²; WEJ Hanselaar³; WNM Dinjens¹

¹Erasmus MC/Department of Pathology, Rotterdam, Netherlands; ²Sint Franciscus Gasthuis/Department of Pathology (Pathan), Rotterdam, Netherlands; ³Sint Franciscus Gasthuis/Department of Pulmonary Medicine, Rotterdam, Netherlands

Histological and molecular subtyping of non-small cell lung cancer (NSCLC) is important for predicting survival and drug response in these patients. Up to 8% of NSCLC are multifocal and these tumour foci are often clonally related. Multiple foci can however also represent different primary tumours, which has prognostic and therapeutic consequences. We describe a patient with multifocal NSCLC and addressed the question whether these foci are clonally related using routine molecular analysis. Furthermore, targeted next generation sequencing with the Ion Torrent Personal Genome Machine (PGM) was performed to explore the accuracy and additional value of this relatively new technique. The two tumours of this patient showed different activating epidermal growth factor receptor (EGFR) mutations, EGFR amplification status, TP53 mutation status and loss of heterozygosity patterns. With the PGM all conventional detected mutations were confirmed, and an additional variant of unknown significance in ATM was detected in a minor subset of one of the tumours.

The multifocal NSCLC of this patient represents two unrelated primary tumours. We conclude that multifocal NSCLC should be considered as potentially multiple primary tumours. As the presence of activating EGFR mutations has important therapeutic consequences, EGFR testing ought to be performed on all tumour foci present. Targeted next generation sequencing using the PGM is accurate and can be of additional value in diagnostic questions regarding tumour clonality, especially when no mutations are detected using routine molecular techniques.

P34

Regulation of Folate Pathway Related Genes in Methotrexate Naïve and Methotrexate Treated Patients with Rheumatoid Arthritis

© M Blits¹; G Jansen¹; YG Assaraf²; WF Lems¹; MT Nurmohamed³; D van Schaardenburg⁴; AE Voskuyl¹; GJ Wolbink⁴; S Vosslander¹; CL Verweij¹

¹VU University Medical Center, Amsterdam, Netherlands; ²The Fred Wyszkowski Cancer Research Laboratory, Technion-Israel Institute of Technology, Haifa, Israel; ³Reade/VU University Medical Center, Amsterdam, Netherlands; ⁴Reade, Amsterdam, Netherlands

Purpose of study: Rheumatoid arthritis (RA) is one of the most prevalent systemic autoimmune disorders. Folate antagonist methotrexate (MTX) is an anchor drug in the treatment of RA. Here, we aim to provide insight into the cellular pharmacological effects of MTX by gene expression analysis.

Methods: We investigated the expression of 17 genes in the folate pathway by peripheral blood cells in a cohort of MTX-naïve and MTX-treated RA patients, and healthy controls (HC). For the test cohort we used a gene expression microarray approach. Multiplex real-time PCR was used in the validation cohort.

Summary of results: Multiple folate metabolism-related genes were significantly altered between the three study groups. We observed an inflammation-triggered increased expression of the folate metabolizing enzymes gamma-glutamyl hydrolase and dihydrofolate reductase, as well as the MTX/folate efflux transporters ABCC3 and ABCC4 the MTX- RA group compared to HC. Most interestingly, MTX treatment normalized these differential gene expression levels to those observed in HC. These results were confirmed in an independent validation cohort.

Conclusions: These results for the first time reveal that under inflammatory conditions, basal folate metabolism in blood cells of RA patients is markedly upregulated, and suppressed upon MTX treatment. Acknowledgements: Prof. Dr. Y.G. Assaraf received a visiting professor fellowship provided by the Dutch Arthritis Foundation. This study is partly supported by the "TRACER" consortium of the Center for Translational and Molecular Medicine (CTMM), and the Dutch Arthritis Foundation.

P35

Systemic Inflammation and B-cells in Rheumatoid Arthritis

© M Blits¹; S Vosslander¹; J Lubbers¹; S de Ridder¹; GJ Wolbink²; D van Schaardenburg²; MT Nurmohamed³; CL Verweij¹

¹VU University Medical Center, Amsterdam, Netherlands; ²Reade, Amsterdam, Netherlands; ³Reade/VU University Medical Center, Amsterdam, Netherlands

Purpose of the study: Rheumatoid arthritis (RA) is heterogeneous in clinical symptoms and parameters, pathogenesis and expression levels. Previously, we demonstrated variation in B-cell related gene expression between RA. The aim was to explore the relation of B-cell related gene expression to clinical parameters of disease severity in early arthritis (EA) and established RA (esRA).

Methods: B-cell related gene expression (B-cell score) was determined in peripheral blood of 26 EA and 180 esRA patients, using multiplex real-time PCR. For EA, B cell counts were also measured using flow cytometry. The esRA cohort was (randomly) divided into test and validation group of each 90 RA patients, with a mean DAS28 of 5.0 and 5.2, respectively. B-cell scores were correlated with clinical disease parameters DAS28, CRP, RF, anti-CCP, nodules and erosions in all cohorts and B-cell counts only in EA cohort. Summary of results: We demonstrated that the B-cell score reflected the peripheral blood B-cell count ($p < 0.0001$, $r = 0.7463$). In EA the B cell score revealed a significant negative correlation with CRP ($p = 0.0175$; $r = -0.4618$). In the esRA group we also observed a negative correlation between the B cell score and CRP levels ($p = 0.0006$, $r = -0.3542$; $p = 0.0096$ after multiple testing correction). This result was confirmed in the independent validation group ($p = 0.0356$; $r = -0.2218$). No correlations between B cell score and DAS28, RF, anti-CCP, nodules and erosions were found.

Conclusions: A low B cell count is associated with an increased marker of systemic inflammation in RA.

P36

The Hierarchical Model of Stem Cell Genesis Answers Peto's Paradox, the Red Cell Paradox, the Man-Mouse Paradox and Explains Wright's Enigma.

© MJ Acres¹; JJ Heath¹; JA Morris²

¹Lancaster University, Lancaster, United Kingdom; ²University Hospitals of Morecambe Bay NHS Foundation Trust, Lancaster, United Kingdom

Carcinoma increases in prevalence as a power function of age (n). This can be explained if carcinoma arises in a single stem cell due to the accumulation of a specific set of deleterious mutations (m can be greater or less than n). This concept has been confirmed; carcinoma is clonal and requires at least four deleterious mutations. There are, however, difficulties. Peto pointed out that carcinoma rises as a power function of age but is closer to a linear function of mutagen dose (Peto's paradox). There are more mitoses in the stem cells of the red cell series than in all other stem cells combined and yet erythroleukaemia is rare (red cell paradox). The prevalence of carcinoma is similar in mice and in men even though men are 1000 times larger and live 30 times as long (the man-mouse paradox). In the gastro-intestinal tract some clonal tumours have a multi-clonal origin (Wright's enigma). The problem is the conventional view that stem cells cycle every few days with thousands of mitotic divisions separating stem cells in old age from the zygote. We propose a different model, illustrated in this poster, in which the number of cell divisions separating mature cells in old age from the zygote is $\log(2)N$, where N is the total number of cells produced in a human lifetime. This model, with fewer than 60 divisions answers the paradoxes and explains Wright's enigma. It predicts that carcinoma will be rare in epithelial cell populations unless the stem cell hierarchy is disrupted by inflammation, ulceration or trauma.

P37

Models of Stem Cell Kinetics: Spermatogenesis and Carcinogenesis

© JJ Heath¹; MJ Acres¹; JA Morris²

¹Lancaster University, Lancaster, United Kingdom; ²University Hospitals of Morecambe Bay NHS Foundation Trust, Lancaster, United Kingdom

The conventional model of epithelial cell generation envisages a regularly cycling stem cell producing the mature cells of an anatomical niche. If the cell cycles daily it would undergo 3,000 mitotic divisions in 82 years of human life. By contrast the hierarchical model of stem cell genesis (presented in a companion poster) produces mature human cells with no cell more than 60 divisions from the zygote even in extreme old age. In this poster we have estimated the rate at which new deleterious mutations arise in spermatogenesis and are passed to the next generation. The estimates are based on the frequency of recessive disease in the offspring of cousin marriages. To do this we derived simultaneous equations relating L (the mean number of deleterious mutations in the zygote), M (the mean number of new deleterious mutations arising in gametogenesis and passed to the next generation) and P (the number of genes in the diploid genome). M is between 6 and 10, and L between 0.5 and 1.5 if P is less than 60,000. Even low rates of mutation (5×10^{-7}) put the upper limit of the number of mitoses between zygote and spermatozoa at 60. We have also used models to predict rates of colonic carcinoma and erythroleukaemia using data on the number of cells produced per day and assuming two hit and four hit models of malignancy. The hierarchical model is a much better fit to the data than the conventional model.

P38

A Rare and Aggressive Cervical Cancer

S Ghosh; © BLR Ahmed

Russell Hall Hospital, Histopathology Department, United Kingdom

A multiparous woman in her late 20s presented with lower abdominal pain, disrupted menstrual cycle, constitutional symptoms and vaginal discharge for 2 years. Microbiology swab results were negative and pelvic ultrasound was unremarkable. Papanicalou (PAP) smear showed severe dyskaryosis. Vaginal examination showed a large friable mass which was initially mistaken for a fibroid polyp. However, histology revealed it was a small cell carcinoma of the cervix.

Small cell carcinoma of the cervix is a rare and aggressive form of carcinoma and makes up only 2% of all cervical malignancy. It most commonly arise in lung cancers but sometimes occur in cervix, prostate and gastro intestinal tract cancers.

The case study demonstrate the presentation of this cancer in a young female and it was thought to be a cervical polyp initially. Preliminary tests such as Papanicalou test and ultrasound scan are not sensitive enough to diagnose this rare but aggressive form of cervical carcinoma. The objective of this case study is to reveal importance of thorough investigations and to educate clinicians that a condition does not normally present as described in literature.

P39

Buruli Ulcer In Sierra Leone: An Unique Undergraduate Elective Project Prize-winning Pathological Society Award for Best Elective Report 2011

© HE Murphy

Royal Shrewsbury Hospital, Shrewsbury, United Kingdom

Background:

Mycobacterium Ulcerans, or Buruli Ulcer, is a neglected tropical disease and the third most common mycobacterial infection after TB and Leprosy. The disease is characterised by slow development of a painless ulcer, leading to severe disfigurement, disability, and, rarely, death. The disease affects younger people, therefore crippling socio-economic development. Treatment includes early excision, long term antibiotic therapy, and surgical debridement of large wounds. No data exists confirming the presence in Sierra Leone. Purpose of the study: To investigate the presence of Buruli Ulcer in Sierra Leone.

Methods:

Patients enrolled from a remote hospital ulcer clinic, and via community outreach over an eight-week period. A questionnaire was used to screen patients and collect epidemiological data. Exclusion criteria included pain, and other causes of anaesthesia of the limbs. Consent was obtained.

Ulcers meeting the study criteria were examined, measured, swabbed with sterile dry cotton swabs, and photographed. Acid-fast bacilli and auramine-phenol staining of samples performed in basic laboratory, following guideline prepared in Microbiology Dept, Plymouth, UK. PCR samples sent to Ghana to confirm species.

Summary of Results:

17 ulcers met criteria. Most patients affected worked with limbs submerged in water. 3 cases positive for mycobacterium; 2 on AFB and one on AFB and auramine phenol. All 17 patients samples sent for PCR; all returned negative.

Conclusions:

Significant burden of unknown painless tropical ulcers in Sierra Leone. Lack of knowledge of Buruli Ulcer and lack of treatment e.g clean bandages, antibiotics. Buruli Ulcer research is underfunded, and therefore use of PCR is rare. Few PCR-confirmed cases of Buruli Ulcer documented in the literature. This study brings into question the reliability of simple laboratory tests for diagnosis

P40

A Study of Double Reporting Practise in our Histopathology Department.

© F Alchami; E Youd; R Trefor

Royal Glamorgan Hospital, Llantrisant, United Kingdom

Introduction: Double reporting in Histopathology is a form of secondary opinion used to minimise errors. Studies reviewing the practice of histopathology reporting showed an error rate ranging between 1.4 to 2.2 % 3.4. Most of the studies were based on a review of slides after issuing the report and prior to the MDT. The practice of formal or informal case discussions of the histopathology diagnosis with colleagues within a department, is not fully studied. Our policy requires review of all diagnostic breast biopsies, all prostate cores, new diagnosis of cancer and melanomas.

Aims and methodology: Our aim is to establish the value and efficiency of our local policy. 1000 consecutive cases were chosen randomly in the year 2011. The back of the paper request forms and the final report on telepath were examined. The cases where a second opinion was requested and given were logged onto a spreadsheet to include the specimen number, type, reporting pathologist, pathologist giving second opinion, opinion of reporting pathologist, second opinion, and final report. The difference of opinion was then divided into minor and major.

Results: Out of a total of 1000 cases examined, 109 (10.9%) required a second opinion, 90% departmental policy, and 10 % consultant choice. Breast biopsies 30%, prostate cores 27%, colon, skin, and bladder biopsies 7% each. These cases were reported by 9, on average each consultant requested 12 second opinions (1- 18), and gave 12 second opinions (0-30). There was a difference of opinion in 17 15% (17 / 109) of all cases where a second opinion was requested of which 2.7% a major error. These were in breast and bladder biopsies. The time implication workload of 21 to 35 hours in a month.

Conclusion: Double reporting provides a mechanism of avoiding 2.7% error rate mainly in breast and bladder biopsies, However it is time consuming and can affect the confidence and morale of some pathologists.

P41

Comparing Samples of Different Read Lengths Affects Quality of Data Generated Using Next Generation Sequencing

© W Fateen¹; S Berri²; H Wood²; M Taylor¹; GR Taylor³; P Quirke³

¹Section of Pathology and Tumour Biology, Leeds Institute of Molecular Medicine, Leeds, United Kingdom; ²Section of Pre-Cancer Genomics, Leeds Institute of Molecular Medicine, Leeds, United Kingdom; ³Section of Translational Genomics, Leeds Institute of Molecular Medicine, Leeds, UK, Leeds, United Kingdom

Purpose of the study:

Next generation sequencing (NGS) provides a flexible platform and generates large amounts of data.

Approximately 40 million reads are randomly generated per lane on the Illumina GAIIX genome analyzer flow cell. Samples can be multiplexed within each lane and hence a variable number reads per sample is generated. Read lengths can be variable between different NGS runs.

In this test we aim to investigate the effect that variability in read lengths will have on the quality of data generated.

Methods:

DNA libraries from 2 formalin fixed, paraffin embedded samples micro-dissected from a single block of a normal human heart were sequenced using Illumina GAIIX on two separate runs. The control sample was constructed from a pool of 20 normal British males (POM) downloaded from the 1000 Genomes Project.

We calculated the ratio between the number of reads of a sample and the control (POM). The obtained signal was segmented and results from both samples compared. We expected the ratio between these two samples to be 1, but observed that a large number of segments had a ratio > 1.2 or < 0.8. We trimmed the length of the reads to the same value across samples and control, and re mapped the reads.

Results:

By comparing the frequency diagrams pre and post trimming we found that there was a significant drop in outliers with odd ratios of > 1.2 or < 0.8.

Conclusion:

Quality of data generated using NGS can be improved by trimming the data to similar read lengths, which although reduces the information content, it also removes a mapping bias and results improve, this would decrease the possibility of false interpretations of copy number variations.

P42

Quality of the Early Stages of Specialty Training: Year One Histopathology Trainees National Survey

O Dotsenko¹; R Colling²; M Barrow³; © L Moore⁴; S Cossins⁵; M Young⁶; S Holden⁷; A McGregor⁸

¹Sheffield Teaching Hospitals, Sheffield, United Kingdom; ²University Hospitals Bristol NHS Foundation Trust, Bristol, United Kingdom; ³The Central Manchester and Manchester Children's University Hospital NHS Trust, Manchester, United Kingdom; ⁴Addenbrooke's Hospital, Cambridge, United Kingdom; ⁵Leeds Teaching Hospitals NHS Trust, Leeds, United Kingdom; ⁶Royal Free London NHS Foundation Trust, London, United Kingdom; ⁷Southampton General Hospital, Southampton, United Kingdom; ⁸Leicester Royal Infirmary, Leicester, United Kingdom

UK Histopathology services face changes in structure and working patterns. There is a need for high quality specialty training to provide an adequate workforce meeting new expectations.

We surveyed doctors in Stage A Histopathology Specialty Training (ST1) across England, Wales and Northern Ireland to find out what they think about the quality of their training. Trainees were asked to complete the survey using an internet based questionnaire. The survey had 75 questions about: Induction; Teaching; Supervision/Assessments; Work Experience/Environment; Generic skills acquisition; Job satisfaction.

Results. 56 trainees completed the survey out of 72 who were eligible (response rate=78%). Most of the responders found the quality of Induction to be good and suggested areas of improvement. The frequency of formal teaching varied across the Deaneries, ranging from none to every day teaching. Most of the trainees rated Block Teaching Weeks (BTW) as very good-satisfactory. 71% of responders did not want to see replacement of BTW by e-learning. 83% of responders were satisfied with the support of their educational supervisor (ES), but, 7.4% had no meetings with their ES during their ST1 year. Only 18% of responders said that work-based assessments were a good reflection of their progress. 42% of responders said they did not receive training in all Stage A curriculum areas prior to the Year One Assessment (OSPE). Difficulties in preparation for the OSPE and with autopsy and cytology training were discussed. 13%, 15% and 8% of responders said they did not have enough experience in non-cervical, cervical cytology and autopsy training, respectively. 71% of responders felt that Histopathology offered a better life/work balance compared with other specialties. Conclusions. This survey identified specific aspects of early stages in Histopathology Specialty Training to be addressed in the advent of a changing service environment.

P43

An Audit of 'Use of NHS Numbers on Histopathology Request Forms'

© AS Azam¹; AH Youssef¹; SB Absar²

¹Russells Hall Hospital, Dudley Group NHS Foundation Trust, Dudley, United Kingdom; ²Dudley Group NHS Foundation Trust, United Kingdom

INTRODUCTION: The NHS Number is the only national unique patient identifier in operation in the NHS. Using the NHS Number makes it possible to share patient information safely, efficiently and accurately across NHS organization. The complete adoption of the NHS Number was included as a key priority as part of the NHS Operating framework 2008/9.

OBJECTIVES: 1. To see how frequently histopathology request forms arrive with NHS number of patient. 2. To establish how often these numbers are put on by the Histopathology department staff. 3. To see who is doing better than others (DGH, GPs.)

STANDARD: All the Histopathology forms must include the NHS number of the patient.

Target: 100%

METHODOLOGY: Prospective audit done over 1 month (September 2011) at Histopathology department. All the Histopathology request forms arriving in the laboratory were included and patients with no NHS number were excluded.

RESULTS: A total of 4613 request forms were received by the Histology Lab over 1 month. 4537 (98.3%) of the forms included NHS number, 76 (1.7%) of the forms did not include NHS number. Average time spent on chasing each NHS number was 3-5 min. (Avg 6.33 hours each month). In terms of individual users performance, from primary care 100% request forms included NHS number whereas from hospital the results were: out patient clinic 99% and theater 97% of the request forms included a NHS number.

CONCLUSION: In view of NHS numbers' importance and the emphasis put on in recent reports, fortunately our results are great. There are small areas where we certainly can improve like theater samples where emphasis needs to be put on relevant teams to anplan an independent audit to evaluate their improvement.

RECOMMENDATIONS: 1. Results need to be passed on to the teams who are falling behind the recommendations. 2. Re-audit: Need to be done again in 6 months time.

P44

An Audit on Rejected Histopathology Specimens

© BLR Ahmed; S Ghosh

Russell Hall Hospital, Histopathology Department, United Kingdom

Background

'Histopathology is the diagnosis and study of disease by expert medical interpretation of cells and tissue samples'. Samples are sent to the laboratory in special containers and to avoid errors all samples and all request forms require proper labelling.

Rationale

It was noticed, at a hospital in Dudley, that there was a high number of rejected samples in the histopathology department. Hence an audit was undertaken to assess the problem.

Aim and Objective

To ensure that the Trust is conforming to the local guidelines and to identify the reason behind the high number of rejected samples.

Standard

- 1 All Products of Conception requests require an accompanying consent form
- 2 The mandatory High Risk box needs to be filled
- 3 The request form and the specimen details must match
- 4 The details on the form and the container need to be legible and need to have the requestor's signature

Method

Retrospective data, by using the laboratory log book on rejected samples, was collected for the time period 1st January 2012 till 18th August 2012. All rejected samples, from both hospital and primary care, were analysed.

Results

64 samples were returned to their senders. 31 were from GP and 33 from Hospital. It was observed that the highest return rate from Hospital specimens were those containing products of conception but did not have an accompanying consent form and those request forms which did not have the high risk box ticked. From the primary care, un-ticked high risk box was the main reason for returned samples, closely followed by details on container and request form not matching.

Implications

Non conformance to the guidelines put both the safety of staff and patients at risk and can lead to unnecessary delays. This has a negative impact on patient care. Recommendations and action plan was to educate doctors about the importance of proper labelling and proper filling out of the forms.

P45

An Audit of Case Prioritisation and 'Chased' Histopathology Requests

RD Liebmann; K Hamon; © N Heatley

Maidstone Hospital, Maidstone, United Kingdom

To manage a transient but significant increase in the workload per histopathology consultant in this department a system of prioritisation was developed and implemented. On the basis of the clinical information provided specific criteria were used to allocate cases into two groups: Priority versus Routine. Routine cases were those which it was felt could wait for reports to be issued without compromising patient safety and which, if required, could be sent safely to a remote locum agency for reporting. During the same period, requests for outstanding reports ('chased cases') required by a variety of clinical teams were telephoned to a single point of contact in the department, enabling the formation of a comprehensive record of such inquiries.

The effectiveness of the prioritisation system was audited by examining the nature of the 'chased' cases during its use. In the absence of published standards on case prioritisation in histopathology at the time, the standards applied in this audit were: 1) Routine cases should not be 'chased' by clinical teams. 2) Cases should only be 'chased' by clinical teams when delayed beyond a reasonable diagnostic turnaround time. 3) Only unauthorised cases (not available to be viewed on the Laboratory Information Management System) should be 'chased' by clinical teams.

The results of this audit show that no cases classified as Routine were 'chased'. The results also show that a significant proportion of 'chased' results were for cases that had not yet exceeded the agreed time-frame for reporting. For the purposes of the audit the RCPATH Key Performance Indicators (broadly defined as 7 days for biopsies and 10 days for excisions) were taken to be the turnaround time standard.

This audit provides evidence that the system of prioritisation was effective in identifying cases of clinical priority likely to be actively followed up by clinical teams.

P46

Quality of Pathology Reporting for Non-benign Ovarian Tumours

© C Ryan¹; S Phelan²

¹Galway University Hospital, Cork, Ireland; ²Galway University Hospital, Galway, Ireland

Purpose of the Study:

To assess the quality of pathology reporting of non-benign ovarian tumours in Galway University Hospital

Methods:

Database search was undertaken for all ovarian resections with primary ovarian non-benign tumours, reported from January 2010 to December 2011. Pathology reports were compared to the RCPATH document "Datasets for the histopathological reporting of neoplasms of the ovaries and fallopian tubes and primary carcinomas of the peritoneum (3rd edition)".

Results:

31 ovarian resections were included, comprising 12 borderline and 19 frankly invasive tumours.

While the majority of reports were broadly adherent to guidelines, gross assessment of capsular integrity, cross-referencing peritoneal cytology, and staging according to FIGO system were problematic. For example, the capsule integrity was mentioned in gross description in only 17/31 cases. Reference to peritoneal cytology was mentioned in less than 10% of reports (3/31). FIGO staging was given in only 16/31 cases.

Conclusions:

At present a proforma or template is not used in the department for either grossing or reporting histology of ovarian non-benign tumours. Different consultants vary in how they report these tumours. A template may be useful. Trainees may benefit from a reminder of the importance of mentioning capsule integrity when grossing.

Consultants need to cross-reference peritoneal cytology in reports, and remember to include figo stage.

P47

Virilising Oncocytic Adrenocortical Tumour, a Diagnostic Pitfall

© F Alchami; A Boyde; R Trefor

University Hospital of Wales, Cardiff, United Kingdom

Introduction: Oncocytic adrenocortical tumour (OACT) is a diagnostic pitfall in pathology due to features that can be interpreted as a malignancy, if the commonly used Weiss criteria¹, is used. Various studies have addressed this diagnostic difficulty. The Royal College of Pathologists dataset for adrenal cortical carcinoma¹ advised the use of the criteria proposed by Bisceglia et al², which relies on minor and major histological criteria. Duregan et al³ in a study of 27 OACT proposed the complimentary use of reticulin staining to decrease the subjectivity and inter-observer variability.

Presentation: We present a 25 years old female with a history of changing hoarse voice and amenorrhoea. Serological investigations showed high testosterone levels. An MRI scan showed a 6 cm left adrenal tumour. Adrenalectomy was performed and was followed by good recovery.

Macroscopic examination showed a 6cm well circumscribed tumour nodule with fleshy, orange, smooth cut surface, weighting 90gr. Microscopically the tumour was composed of organised sheets of oncocytic cells with eosinophilic cytoplasm, pleomorphic nuclei, prominent nucleoli, and a mitotic rate of 3/50 HPF in a delicate capillary network. On face value these features are worrying (diffuse architecture, nuclear pleomorphic, prominent nucleoli) and mislead to a diagnosis of malignancy, on applying the Weiss system, if the oncocytic nature was not recognised. Conversely upon using Bisceglia or Duregan criteria the diagnosis is concluded to be that of a benign oncocytic adrenocortical tumour.

Conclusion: Oncocytic adrenocortical neoplasms are rare tumours whose oncocytic characteristics should be recognised and acted upon when choosing the relevant criteria to establish their malignant potential.

References:

1 Int J Surg Pathol 2004;12:231-243.

2 Am J Surg Pathol. 2011 Dec;35(12):1882-93.

3 Histopathology (2009) 55, 535-543

P48

Integration of Human Papillomavirus Type 16 in Oropharyngeal Squamous Cell Carcinomas does not Invariably Result in High Levels of Viral Gene Transcripts

© EJM Speel¹; NC Olthof¹; CU Huebbers²; J Kolligs²; A Haesevoets¹; M Henfling¹; FCS Ramaekers¹; SF Preuss³; U Drebber³; W Lam⁴; E Vucic⁴; B Kremer¹; JP Klussmann⁵

¹Maastricht UMC, Maastricht, Netherlands; ²Jean Uhrmacher Institute, Cologne, Germany; ³University of Cologne, Cologne, Germany; ⁴BC Cancer Center, Vancouver, Canada; ⁵University of Giessen, Giessen, Germany

Purpose of the study. Infection with HPV type 16 is an independent risk factor for the development of oropharyngeal squamous cell carcinomas (OSCC). The role of HPV16 DNA integration into the human genome is to date unclear. It is not sufficiently studied whether viral gene expression levels are correlated to the viral physical state, if integration promotes tumorigenesis and whether integration occurs at preferred genomic localizations.

Methods. For this purpose, we have examined HPV16-PCR- and p16INK4A-positive OSCC samples of 75 patients. Viral-human fusion sequences that are a result of integration we detected using DIPS-PCR and APOT-PCR on DNA and RNA isolated from fresh frozen OSCC. In addition, we have used FISH on formalin-fixed, paraffin-embedded tumors to examine the presence of punctate nuclear signals indicating viral integration. Expression of viral E2, E6 and E7 genes were examined by RT-PCR.

Results. HPV16-human fusion products indicating viral integration were identified in 29 of 75 OSCC (39%), with a total of 37 fusion products. The identification of a fusion product, however, did not result in altered expression of the viral genes E2, E6 and E7. Independent of the presence of a fusion product, viral gene expression could be detected in most OSCC. In addition, identified integration sites were distributed over the whole genome, 27 (73%) of which were found in protein-encoding regions, often with reported involvement in tumorigenesis, including BCL2, FANCC and TP63. FISH analysis showed punctate signals in 55 of 61 OSCC (90%) indicative of integration.

Conclusions. In conclusion, a viral-human fusion product can be identified in approximately 40% of the HPV-16- and p16INK4A-positive OSCC, with integration sites distributed over the entire genome. Nevertheless, the presence of a viral-human fusion product does not seem to be linked to deregulated viral gene expression.

P49

Thyroid Like Low Grade Tumours of Nasopharynx Causing Confusion With Metastasis From Thyroid Carcinoma.

© SJ Appukutty; S Di Palma; L Pitkin

Royal Surrey County Hospital, Guildford, United Kingdom

Introduction:

Low-grade papillary adenocarcinoma of the nasopharynx (LGPACNP) is a rare neoplasm. Based on the immunohistochemical feature of nuclear positivity for thyroid transcription factor-1 in conjunction with the histological characteristics of papillarity, psammoma bodies, neoplastic cells with overlapping nuclei and clear chromatin, the term "thyroid-like nasopharyngeal papillary adenocarcinoma" was coined.

Materials and Methods:

Clinical history was retrieved from discussion in Head and Neck MDT meeting and medical records. Routine macroscopic and microscopic histological examination with appropriate immunohistochemistry was performed. In addition, we include the review of literature for the low grade nasopharyngeal tumour from English literature.

Result:

We present a case of thyroid-like low grade nasopharyngeal papillary adenocarcinoma in a 49 year old male, who presented with snoring. The tumour cells were, strongly and diffusely positive for TTF-1; but were negative with antibodies to thyroglobulin.

Conclusion:

It is important to recognise this rare entity; as these tumours are amenable to surgical resection and have an excellent prognosis. There is little familiarity of this tumour type among general pathologist and get referred for specialist reporting; we aim to create familiarity of this uncommon tumour type which may be confused with a metastasis from thyroid.

P51

Basal Cell Carcinoma Metastatic to Parotid Gland

© RR Kurian¹; SJ Appukutty¹; S Di Palma¹; B Barrett²

¹Royal Surrey County Hospital, Guildford, United Kingdom; ²Queen Victoria Hospital NHS trust, East Grinstead, United Kingdom

Introduction – Basal cell carcinoma is one of the commonest cutaneous malignancies. It has a very low risk of metastasis with cases being documented in sites such as lymph nodes, lung, bone and parotid gland. Here we present a case of basal cell carcinoma of eyelid which metastasized to an intraparotid lymph node with infiltration of the parotid parenchyma.

Material and Methods - Clinical history was retrieved from discussion in Head and Neck MDT meeting and medical records. Routine macroscopic and microscopic histological examination with appropriate immunohistochemistry was performed. **Results** – A 68 year old man presented with left ocular basal cell carcinoma which was treated by orbital exenteration. He later presented with full facial nerve palsy and underwent a left total parotidectomy with excision of overlying skin and left neck dissection which revealed metastatic carcinoma in an intraparotid lymph node.

Discussion – Metastasis of basal cell carcinoma to parotid gland is very rare with only less than 300 cases reported in literature. The main histological differential diagnosis is the locally arising primary basal cell adenocarcinoma of parotid gland. Features favouring metastasis include a history of primary cutaneous basal cell carcinoma, histological similarity to the primary cutaneous lesion and the absence of any demonstrable direct extension from the skin lesion. More awareness and vigilance is required on the part of the reporting pathologist for diagnosing this rare entity

P50

Audit of Histopathology Reporting of Neck Dissection Specimens Associated with Head and Neck Carcinoma.

© SJ Appukutty; RR Kurian; S Di Palma

Royal Surrey County Hospital, Guildford, United Kingdom

Purpose of the study

The National Minimum Dataset for the Histopathology reporting of nodal excisions and neck dissection specimens associated with head and neck carcinomas was published by the RCPATH in December 2011. Our aims were to assess the completeness of neck dissection histopathology reports in the department of histopathology at the RSCH as compared to the RCPATH Minimum Dataset.

Methods

76 consecutive neck dissection specimens for squamous cell carcinomas of the head and neck area was analysed (January 2011-April 2012). The core data items reviewed were

- Anatomical level of the node
- Total number of node/number of metastatic nodes
- Size of largest metastatic deposit
- Extracapsular spread
- Diagnostic coding of metastasis.

Summary of results

The anatomical level was well marked in 93.4%. The total number of lymph nodes and the number involved by metastasis were noted in all the cases. Amongst the lymph node which had metastasis size of metastatic deposit and extracapsular metastasis were mentioned in 69.4 and 85.7 % respectively.

Pathological coding was mentioned in 55.3%. Intraparotid metastases were not coded.

Conclusion

Standards of reporting were generally good, but continued vigilance is required to ensure that high standards are maintained. A re-audit is recommended in 2013.

P52

Malignant Epithelial Salivary Gland Neoplasms in a Tertiary Hospital in Sub-saharan Africa

© KC Akpobi¹; K Abdullahi²; MS Shehu²; MOA Samaila²; U Mohammed²

¹Department of Pathology Ahmadu Bello University Teaching Hospital, Zaria, Nigeria; ²Ahmadu Bello University Teaching Hospital, Zaria, Nigeria

In view of their overlapping and complex morphology, malignant epithelial salivary gland neoplasms pose considerable diagnostic and management challenges to the pathologist and surgeon. The aim of this study is to evaluate the frequency and histopathological patterns of all types of malignant epithelial salivary gland neoplasms by patient's age, sex and site of presentation and compare the findings to similar studies locally, regionally and globally. This is a retrospective histopathological review of malignant epithelial salivary gland neoplasms over a twenty-year period (1989 to 2008) in a tertiary hospital in sub-saharan Africa.

A total of 131 cases were diagnosed and studied within the period. The most common cancers seen are adenoid cystic carcinoma 67(51.15%), mucoepidermoid carcinoma 47(35.87%), polymorphous low grade adenocarcinoma 5(3.82%) and adenocarcinoma NOS 5(3.82%). The least common cancers seen are acinic cell carcinoma, clear cell carcinoma and sialoblastoma each with 1(0.76%) respectively. Most cases seen are between ages 31 to 50 with 63 cases (48.2%). The male to female ratio is 1.5:1. The site of tumour involvement are parotid 67(51.14%), minor salivary glands 43(32.82%), submandibular 15(11.45%), neck 3(2.29%) and unspecified 3 (2.29%).

Malignant epithelial tumours of the salivary gland are diverse. This study demonstrates that adenoid cystic carcinoma and mucoepidermoid carcinoma are the most common tumours seen respectively, the two representing 87.02% of all tumours diagnosed.

P53

Have We Got it Wrong about Barrett's Esophagus? Patterns of Gene Expression and Stem Cell Organisation Show Barrett's Glands to be a Unique Phenotype

D Lavery¹; A Nicholson²; SAC McDonald¹; R Jeffrey¹; M Jansen³; © NA Wright¹

¹Barts and the London School of Medicine and Dentistry, London, United Kingdom; ²CRUK Cambridge Research Institute, Cambridge, United Kingdom; ³Academic Medical Center, Amsterdam, Netherlands

When we read papers of the histopathology of Barrett's oesophagus, the appearances are usually described as 'intestinal metaplasia', or 'specialised epithelium', and the structures mentioned are almost uniformly referred to as 'crypts'. It is often forgotten that columnar epithelium in Barrett's oesophagus shows evidence of both intestinal and gastric differentiation, and that gene expression within Barrett's glands shows a distinct pattern. In Barrett's glands we have studied the distribution of proliferative activity using Ki67 immunohistochemistry (IHC), of mucin and trefoil family factor (TFF) peptides using IHC and in situ hybridisation (ISH) and the localisation of the stem cell marker LGR5 using ISH, in conjunction with analysis of the clonal architecture of Barrett's glands using mitochondrial DNA (mtDNA) as a clonal marker. In Barrett's glands proliferation is seen mainly in the middle part of the gland and diminishes towards the surface and the base of the gland. MUC5AC and TFF1 expression are found superficially, while MUC6 and TFF2 are found at the bases of the glands: MUC2, staining goblet cells and columnar cells, is concentrated superficially. LGR5 is also found in the middle part of the glands, suggesting that this may be the location of the stem cell niche. Barrett's glands are clonal, indicating derivation from a single cell, suggesting that Barrett's stem cells have dual differentiation capacity. Complete gastric intestinal metaplasia, on the other hand, shows basal LGR5 location with a distribution of proliferative activity similar to intestinal crypts. We conclude that Barrett's glands show a unique gland architecture maintained by stem cells with both gastric and intestinal differentiation capacity, a concept critical for the understanding its origin and development, and indeed for accurate histopathological appraisal.

P54

Endoscopic Therapy of High Grade Barrett's Dysplasia and Early Invasive Adenocarcinoma in a Tertiary Centre

HC McEwan¹; AJ Morris¹; P Glen²; JE Abela³; © JJ Going⁴; G Fullarton¹

¹Glasgow Royal Infirmary, Glasgow, United Kingdom; ²Southern General Hospital, Glasgow, United Kingdom; ³Royal Alexandra Hospital, Paisley, United Kingdom; ⁴University of Glasgow, Glasgow, United Kingdom

Introduction: Endoscopic mucosal resection (EMR) and radiofrequency ablation (RFA) are increasingly used to treat high grade Barrett's dysplasia (HGD) and early invasive (intramucosal/submucosal) adenocarcinoma (early Aca: T1a/T1b, TNM7). We examined efficacy and safety of EMR and RFA treatment of HGD and early Aca in a tertiary centre. Methods: Patients (n=102) with a mean age of 69 years (42-89) with HGD or early Aca (confirmed by a pathologist interested in Barrett's oesophagus) were recruited between July 2008 and September 2011. Nodular areas were removed by EMR with circumferential and focal ablation (HALO 360, HALO 90) of residual Barrett's epithelium to a maximum of 2 HALO 360 and 3 HALO 90 procedures. Results: 72 patients had HGD alone; 30 also had early Aca. Fifty patients completed treatment (median 1 HALO 360 and 1 HALO 90). Of these, 52% had an initial EMR; median follow up was 9 months (3-41). Thirteen of these 50 patients had early Aca (26%). Of the entire patient group, nine (8.7%) experienced adenocarcinoma progression after a median of 12 months, so 59 patients exited the protocol following an intention to treat. Dysplasia was eradicated in 49/59 (83%) and glandular metaplasia in 40/59 patients (68%). Three people died from unrelated comorbidities (2 cardiorespiratory, 1 lymphoma). Eight developed mild oesophageal strictures. One required readmission for retrosternal pain requiring analgesia. There were no serious complications or peri-procedural mortality. Conclusion: Endotherapy with EMR and RFA is an effective and safe alternative to radical surgery in treatment of HGD in Barrett's and early oesophageal Aca.

P55

Length of Cardiac Mucosa in Healthy People Increases with Age and Central Obesity, Supporting the Hypothesis that Cardiac Mucosa is Acquired by a Process of Columnar Metaplasia

EV Robertson¹; MH Derakhshan²; AA Wirz¹; YY Lee¹; SA Hanvey¹; SA Ballantyne¹; © JJ Going³; KEL McColl³

¹Gartnavel General Hospital, Glasgow, United Kingdom; ²University of Glasgow, Glasgow, United Kingdom; ³Glasgow University, Glasgow, United Kingdom

Introduction: Obesity favours reflux-induced oesophageal columnar metaplasia. "Normal" gastric cardia mucosa may be acquired likewise, and predispose to junctional adenocarcinoma. Influence of obesity on development of cardiac mucosa is unknown. Methods: Sixty-two healthy men and women (18-74y) without *H.pylori* had body mass index (BMI) and waist circumference recorded, and 1.5 Tesla MRI measurements of mean visceral and subcutaneous fat in L2, L3 and L4 axial planes. At upper GI endoscopy up to 3 cranio-caudal biopsies of squamo-columnar junction were unrolled and orientated through histological processing. Cardia length was measured if consecutive squamous, cardiac and oxyntic mucosa were all present in one biopsy. Non-parametric correlations were examined of cardia length with BMI, waist circumference and MRI-quantified fat. Stepwise multivariate regression examined age, BMI, waist circumference and MRI fat data as predictors of cardia length. Results: At least one orientated junctional biopsy with squamous, cardia and oxyntic mucosa was obtained for 37/62 volunteers (median length 6.5mm; IQR 1.6). Median cardia length was 2.5mm (IQR 1.5). Length of cardia increased with age (R=0.457, p=0.004), waist circumference (R=0.466, p=0.004), and MRI intra-abdominal fat (R=0.374, p=0.027) and total fat (R=0.389, p=0.021). There was no significant correlation with subcutaneous fat (p=0.091) or BMI. On regression analysis independent predictors of cardia length were waist circumference (standardised coefficient 0.342, p=0.035) and age (standardised coefficient 0.322, p=0.046). Intestinal metaplasia at the cardia was seen in only 4/62 volunteers. Conclusions: Cardia mucosa may be acquired with increasing age through a process of distal squamous-to-columnar metaplasia accelerated by central obesity. A possible mechanism is opening of the distal portion of the low oesophageal sphincter and short segment acid reflux.

P56

Human Crypt Stem Cell Dynamics in Peutz-Jeghers Syndrome

© WWJ de Leng¹; D Langeveld¹; FHM Morsink¹; M Jansen²; GJA Offerhaus¹

¹Department of Pathology, University Medical Centre Utrecht, Utrecht, Netherlands; ²Department of Pathology, Academic Medical Centre, Amsterdam, Netherlands

Genetic predisposition to cancer in Peutz-Jeghers syndrome (PJS) and the role of germline *LKB1* mutations are poorly understood. We therefore studied the effect of germline *LKB1* mutations on intestinal stem cell dynamics in unaffected flat PJS mucosa. Recent research has documented that the intestinal crypt houses multiple equipotent stem cell lineages. Lineages continuously compete through random drifts, while somatically inherited methylation patterns record clonal diversity. An increase in stem cell dynamics may be predictive of an increased risk of neoplastic outgrowth. To study the effect of germline *LKB1* mutations on clonal expansion, we analysed methylation pattern diversity in crypts from unaffected colonic mucosa from archival PJS tissue. We compared methylation pattern diversity in patients with PJS to those in age-matched controls using a sodiumbisulfite treatment followed by either cloning with subsequent Sanger sequencing or a Next Generation Sequencing (NGS) approach. The number of unique methylation patterns is significantly increased for patients with PJS compared to control subjects (p=0,008). Using NGS more unique methylation patterns are found compared to Sanger sequencing (16,5 versus 11,3) and 53% of patterns identified by NGS is found using Sanger sequencing. Monoallelic *LKB1* loss is not silent and provokes a protracted clonal evolution in the crypt. The increased methylation pattern diversity observed in unaffected PJS mucosa predicts that premalignant lesions will arise at an accelerated pace compared to the general population. This assay would therefore be potentially useful for determining tumour risk, which, by using the NGS approach, is feasible within routine diagnostics.

P57

Secondary Malignancies in Mature Teratoma: Implementation of a Genetic Diagnostic Tool

S Dalhuisen¹; GJA Offerhaus²; FHM Morsink²; DJ Richel¹; HJ Klumpen¹; © WWJ de Leng²

¹Department of Medical Oncology, Academic Medical Centre, Amsterdam, Netherlands; ²Department of Pathology, University Medical Centre Utrecht, Utrecht, Netherlands

During a follow up CT scan, six years after a right orchidectomy for a combined teratoma/ seminoma, a retroperitoneal mass was found in a 27 year old male cystic fibrosis patient. Pathological examination revealed a cystic teratoma that contained exocrine pancreas with an acinar cell carcinoma. There were no radiological abnormalities in the pancreas itself. This suggested the development of an acinar cell carcinoma in the metastatic teratoma without a primary in the pancreas, which we confirmed using molecular genetic analysis. The hallmark genetic marker of testicular germ cell tumours is an additional short arm of chromosome 12; isochromosome 12p (i12p), whereas this has not been described for acinar cell carcinoma of the pancreas. We therefore studied the presence of i(12p) by fluorescence in situ hybridization (FISH) using probes specific for chromosome 12 centromeric and telomeric regions.

Isochromosome 12p was found in the primary teratoma as well as in the acinar cell carcinoma component in the metastasis that occurred 6 years later. A normal chromosome 12 was identified in a primary pancreatic acinar cell carcinoma of the control patient, showing genetic evidence of secondary malignancy originating from the primary teratoma.

Occurrence of secondary malignancies in teratomas is a rare but well known phenomenon. To our knowledge, this is the first reported case of an acinar cell carcinoma arising in the metastasis of a testicular teratoma using the FISH methodology as a diagnostic tool. This finding justified our decision not to give adjuvant chemotherapy in this case, and thus it appears a useful method to guide clinicians in the decision of systemic treatment of secondary malignancies of metastatic teratomas.

P58

Absence of GNAS1 Mutations Belies the Functional Importance of This Gene in Colorectal Cancer

© M Jackson; W Fadhil; M Ilyas

School of Molecular Medical Sciences, Nottingham, United Kingdom

The GNAS1 gene codes for the stimulatory alpha G protein subunit of the heterotrimeric G protein family. The G protein family are complexes often bound to 7-pass transmembrane receptors and are involved in the transduction of extracellular signals. Somatic gain-of-function mutations have been described in a variety of malignancies although the frequency of mutation in colorectal cancers (CRCs) is uncertain.

In order to investigate the frequency of GNAS1 mutations in CRC, we tested 22 CRC derived cell lines and 61 primary CRCs. Most mutations occur in hotspots at codon 201 and 227. These areas were therefore interrogated using the QMC-PCR protocol followed by high resolution melting (HRM) analysis. None of the tumours and only of the cell lines showed aberrant melting therefore confirming the low frequency of GNAS1 mutations in CRCs.

The GNAS1 gene maps to chromosome 20q13 – a region which is commonly amplified in CRCs. This led us to hypothesise that an alternative to gain-of-function missense mutations may be gene amplification. We therefore sought to evaluate whether GNAS1 function may influence CRC cell biology. To investigate this, we knocked GNAS1 in 4 CRC cell lines (HCT116, RKO, SW480, SW620). Gene knockdown was undertaken by transfecting small interfering RNAs into the cells and this was followed by an evaluation of cell proliferation. In RKO, HCT116 and SW620, knockdown of GANS1 resulted in a significant reduction of cell numbers in assays conducted over 3 days and 6 days (p<0.05). In SW480, there was no effect on cell number following gene knockdown.

We conclude that GNAS1 may act as an oncogene in CRC. However, in contrast to other malignancies, this oncogenic effect is probably achieved through increased gene dosage via gene amplification rather than constitutive protein activation through missense mutation.

P59

VEGF Expression in lesions of Patients with Colorectal Peritoneal Metastases is Correlated to Survival

© EMV de Cuba¹; IHJ de Hingh²; R Kwakman¹; PM Delis-van Diemen¹; RD Bouwe¹; HJ Bonjer¹; GA Meijer¹; EA te Velde¹

¹VU University Medical Center, Amsterdam, Netherlands; ²Catharina Ziekenhuis, Eindhoven, Netherlands

Purpose of the study: High levels of Vascular Endothelial Growth Factor (VEGF) are associated with a worse prognosis in colorectal cancer (CRC). Anti-VEGF therapies are known to improve the survival in hematogenously disseminated CRC. CRC patients presenting with peritoneal metastases (PM) can be curatively treated with cytoreductive surgery (CRS) and HIPEC. It is not known whether these patients also benefit from treatment with anti-VEGF treatment. We aim to investigate the levels of expression of VEGF in peritoneal deposits and its prognostic value in HIPEC patients.

Methods: From 2007 to 2010 from the Catherina Hospital Eindhoven all consecutive patients undergoing CRS & HIPEC were investigated for VEGF expression. Patients surviving less than 12 months post-treatment were categorized as short survivors and patients surviving more than 12 months as long survivors. These two groups were compared for VEGF expression using the student's T-test. VEGF expression was assessed in selected sections of peritoneal metastases by immunohistochemistry on formalin-fixed paraffin embedded tissue. The intensity of the staining was scored as negative, weak, moderate and strong.

Summary of Results: A total of 49 patients (22 male and 27 female) that underwent CRS&HIPEC for colon carcinoma (n=44) and rectal carcinoma (n=5) were included. The median age was 62 years (range 31-77) and median follow-up was 18 months (range 1-51). Of these patients, 34 survived > 12 months (69%). Moderate to strong VEGF expression was observed in 35 out of 38 successfully analysed cases (92%). Univariate analysis showed that high VEGF correlates with a survival of less than twelve months (p=0,02).

Conclusions: Higher VEGF expression was correlated with a survival of less than twelve months in this group of patients undergoing CRS&HIPEC. The use of anti-VEGF, i.e. Bevacuzimab, in patients undergoing CRS&HIPEC might be of additional clinical value.

P60

Tumour Ploidy Analysis of Microsatellite Stable Colorectal Cancers Identifies a Significant Subset of Diploid Tumours but does not Predict Responsiveness to Radiotherapy

© WM Fadhil; M Ilyas

School of Molecular Medical Sciences, Nottingham, United Kingdom

It is currently considered that Colorectal Cancers (CRC) commonly have genomic instability that manifests as either Microsatellite Instability (MSI) or chromosomal instability (CIN). The two forms are generally mutually exclusive and the former is characterised by near-diploid DNA content whilst the latter is aneuploid DNA. Recently, however, tumours have been described which have neither MSI nor CIN (Microsatellite and Chromosome Stable - MACS). The proportion of tumours with a MACS phenotype is however unknown as is their likely mutation profile.

In order to further investigate the proposed MACS tumours, we investigated the cellular DNA content of 89 CRCs which we had shown to be microsatellite stable. The tumours were analysed using flow cytometry and mutation screening of Kras, Braf, TP53, and PIK3CA was also performed using the QMC-PCR protocol followed by HRM. Overall, there were 51/89 (57%) aneuploid tumours whilst the diploid made up 38/89 (43%). Kras mutation was more frequent in the diploid tumour (23/38) compared to only 19 mutants out of 51 in aneuploid tumours (p=0.03). On the other hand, p53 mutation was more frequent in the aneuploidy tumours (36/51) compared to 19 mutants out of 38 in diploid tumours (p=0.048). There was no association between PIK3Ca, and Braf mutation and tumour ploidy.

Since aneuploidy may result in increased energy and proteotoxic stress in cells, we hypothesised that this may affect the susceptibility of these cells to radiation induced apoptotic death. A total of 33 cases of rectal cancer were tested of which 15 had responded to neoadjuvant chemoradiotherapy (Mandard grade 1 or 2) and 18 had failed to respond (Mandard grade 3-5). The pre-treatment diagnostic biopsies were tested by flow cytometry. Overall 19/33 cases showed aneuploidy but there was no association between tumour DNA content and response to the radiotherapy.

We conclude that MACS form a significant proportion of microsatellite stable tumours. They may have different mutation profiles to the aneuploid tumours but they show no difference in the response to radiotherapy.

P61

Loss of FOXA2 Expression Occurs in Advanced Colorectal Cancers Despite Gene Amplification

© WM Fadhil; M Ilyas

School of Molecular Medical Sciences, Nottingham, United Kingdom

FOXA2 protein belongs to subclass A of the forkhead box containing transcription factor family. Fox proteins are essential for both early embryonic development and late or end-stage epithelial differentiation in many endoderm-derived organs. Although aberrant FOXA2 expression has been observed in prostate and lung cancers, little is known about the role of FOXA2 in colorectal adenocarcinoma.

Fifty cases of paired colorectal primary tumour and corresponding liver metastasis were arrayed onto a tissue microarray (TMA). FOXA2 protein expression was tested by immunohistochemistry and evaluated using the H-scoring method. Nuclear FOXA2 expression was abundant in the normal colonic mucosa and was variable in the tumour samples. The tumours were dichotomised into low (i.e. no expression or score less than the median value) or high (score equal or greater than the median) expression groups. High expression showed a significant association with aneuploidy ($U=195$, $p=0.045$), strong p53 expression ($p=0.022$) and strong BCL2 expression ($p=0.02$). However, FOXA2 expression was lower in the metastatic deposits than the corresponding primary tumours ($Z=-2.202$, $p=0.027$). In order to further investigate this, we tested the all samples for allelic imbalance at the FOXA2 locus (20p11) by quantitative PCR. None of the samples showed allelic loss but unexpectedly, X/y cases showed gene amplification. The matched primary and metastasis showed identical results indicating that this was an early pre-metastatic event. There was however no correlation between the gene copy number and protein expression and in many of the cases showing gene amplification, there was no expression detectable.

We conclude that FOXA2 is a tumour suppressor gene whose loss is associated with tumour metastasis in CRC. Furthermore, this loss of expression occurs despite gene amplification in some cases thereby suggesting an epigenetic method of inactivation.

P62

An Audit of Reporting of Total Mesorectal Excision (TME) Grade in Rectal Cancer Resections.

© AS Azam; V Shinde

Russells Hall Hospital, Dudley Group NHS Foundation Trust, Dudley, United Kingdom

Introduction

The mesorectum is a fatty tissue directly adjacent to the rectum bound by mesorectal fascia. It contains blood vessels and lymph nodes. When rectal cancers recur, it is often in these lymph nodes. Total excision of mesorectum (TME) in rectal cancer resections is associated with reduced rates of local recurrence, better survival and best outcome. TME has become the "gold standard" treatment for rectal cancer.

Aims

To see if TME grading has been reported in rectal cancer specimens at Russells Hall Hospital over a period of one year from July 2010 to July 2011.

Standards & Target

The Royal College of Pathologists has given a minimum dataset to report rectal cancer specimens and it includes the plane of excision, which needs to be reported in each case. The target was 100%.

Methodology

This is a retrospective audit of reporting of TME grade in rectal cancer specimen. The histopathology reports were retrieved from the MasterLab system.

Results

There were 32 rectal cancer resections. 29 cases were included. 3 were excluded as they had Hartmann's procedure. TME / PME grading was reported in 26/29 cases (89.6%) and not reported in 3/29 cases (10.3%) In these 3 cases the tumour was at the rectosigmoid junction.

The grade of TME in these cases were: Mesorectal fascial plane 17 patients (65%), Intra-mesorectal plane 4 patients (15%) and muscularis propria plane 5 patients (20%).

Conclusion

Overall, 89.6% of the cases TME was graded, whereas in 10.3% it was not. The TME reporting was 100% in mid and lower rectal cancer resections. In the 3 cases in which TME was not graded, the tumour was in the recto-sigmoid. The overall target of 100% was not achieved.

Recommendations

1. Pathologists should grade the TME in all cases according to Royal College of Pathologists guidelines.
2. Results to be discussed with the surgical team.
3. To re-audit in a year to check progress.

P63

Can We Predict Residual Tumour Cell Density Following Short Course Radiotherapy in Rectal Cancer Using Clinicopathological and Molecular Markers?

© JD Nicholls¹; E Tinkler-Hundal¹; GJ Hemmings¹;
D Sebag-Montefiore²; P Quirke¹; NP West¹

¹Leeds Institute of Molecular Medicine, Leeds, United Kingdom; ²St. James's University Hospital, Leeds, United Kingdom

Patients with rectal cancer may undergo pre-operative short course radiotherapy (SCRT) to reduce the risk of local disease recurrence, however, there is no effective method at present for predicting response. It was hypothesised that response can be predicted using specific clinicopathological and molecular markers.

A series of 71 patients with rectal adenocarcinoma that received pre-operative SCRT were investigated. Tumour cell density (TCD) and immunohistochemistry (IHC) for protein 53 (p53) and geminin expression were performed on the pre-treatment biopsy (baseline) and post-treatment resection specimen for each case. Good and poor response were dichotomised according to the median TCD in the post-treatment resection.

Median baseline TCD was higher in good responders when compared to poor responders (45% vs. 30%; $p = 0.002$). For p53 IHC, median baseline TCD was greater for high when compared to low expressers (40% vs. 23%; $p = 0.011$). Although non-significant, median baseline TCD for geminin IHC was greater for high when compared to low proliferators (41% vs. 36%; $p = 0.761$). TCD response was better in high p53 expressers when compared to low expressers (good TCD response = 61% vs. 20%; $p = 0.006$). There was a suggestion of a better TCD response in high proliferators when compared to low proliferators although this was not statistically significant (good TCD response = 58% vs. 41%). High baseline TCD and high expression of p53 appears to predict a better response to SCRT in rectal cancer. In addition, high proliferation may predict a better response. Baseline TCD, p53 and geminin therefore all show promise as predictors of response to SCRT. Further large scale confirmatory studies are now required before this can influence selection in routine clinical practice.

P64

Immune Cell Density is Associated with Tumour Cell Density, Histological Subtype, Depth of Invasion and Outcome in Gastric Cancer

© KJ Pettinger; L Ward; A Wright; D Treanor; HI Grabsch

Leeds Institute of Molecular Medicine, Leeds, United Kingdom

Purpose of the study:

The significance of tumour infiltrating lymphocytes has been demonstrated in various cancers including gastric cancer (GC). However, type and abundance of infiltrating immune cells may depend on the tumour microenvironment including tumour cell density (TCD). We hypothesised that immune cells will be more abundant in GC with a high TCD compared to low TCD GC.

Methods: T cells (CD3+), B cells (CD20+), macrophages (CD68+), neutrophils (CD66b+) and tumour cells (pan-Cytokeratin) were identified by immunohistochemistry in 175 primary GCs. Stained slides were digitised. Pixels were classified as immunopositive or negative by automated image analysis. The percentage immunopositive pixels / (immunopositive + negative pixels) per case served as a surrogate marker of cell density. The relationship between TCD and immune cell density (ICD) and the association between TCD normalised ICDs and clinicopathological variables including outcome were analysed.

Summary of results: High TCD was associated with low density of CD68+, CD3+ and CD20+ (all p-values < 0.05). TCD normalised CD20+, CD3+ or CD68+ densities were all higher in diffuse type GC and poorly differentiated GC (all p-values < 0.05). TCD normalised CD66b+ density was higher in poorly differentiated GC only ($p=0.004$). High TCD normalised CD3+ density was related to better overall survival in univariate ($p=0.021$) and multivariate analysis ($p=0.032$).

Conclusions: This is the first study investigating the relationship between tumour cell density (TCD) and immune cell density suggesting that results from immune cell studies in cancer tissues should be normalised by TCD, to be comparable between different tumour types. Our study confirms the independent prognostic value of CD3+ T cells in GC and suggests a relationship between ICD and GC histological phenotype. Whether low TCD is cause or consequence of the higher ICD is currently unknown and warrants further study.

P65

Sponge Sampling to Measure DNA Ploidy of the Oesophageal Mucosa: Potential for Barrett's Oesophagus Risk Assessment

© J Broly; H McEwan; JJ Going

University of Glasgow, Glasgow, United Kingdom

Purpose: Oesophageal cytosponge sampling is a minimally invasive technique to retrieve brushings of the oesophageal mucosa. With DNA ploidy measurements by cytometry or sequencing this could offer an alternative to current endoscopic biopsy and dysplasia-based risk assessment in Barrett's oesophagus. We aimed firstly to develop low-cost DNA image cytometry and assess its precision against flow cytometry. Secondly we investigated 'Oesotest' cytosponge sampling and suitability of the cells retrieved for DNA cytometry and future DNA sequencing studies.

Methods: 'Oesotest' sponge samples from six healthy (non-Barrett) volunteers were placed in liquid based cytology fixative before processing. To measure DNA content of Feulgen stained nuclei, we created a high-throughput image analysis pipeline on the open-source program CellProfiler, optimised on peripheral blood lymphocytes. DNA content of lymphocytes and sponge samples was also assessed by propidium iodide flow cytometry.

Results: Image cytometry measured DNA content of peripheral blood lymphocytes with coefficient of variation (CV) 7.7%, and oesophageal samples with CV 38.2% (95% CI: 26.3-50.1%). For the same samples flow cytometry yielded CVs of 5.1% and 13.7%, respectively. On average flow cytometry varied absolutely by 10.4% less than image cytometry (95% CI: 0.31-21.51%). Total DNA extractable from one oesophageal sponge cytology sample was estimated at 25µg.

Conclusions: DNA content is measurable by a low cost image cytometry assay, but high CVs are unlikely to allow reliable detection of aneuploid sub-populations without substantial optimisation. 'Oesotest' cytosponge retrieves sufficient cell numbers overall for DNA cytometry and enough DNA for sequencing studies, but fixation and processing require further optimisation to realize the full potential of oesophageal sponge cytometry. Use of 'Oesotest' sponges in Barrett's oesophagus remains to be piloted.

P67

Aurora Kinase A (AURKA) Expression in Colorectal Cancer Liver Metastasis is Associated with Poor Prognosis

© JA Goos; V Coupé; B Diosdado; PM Delis-Van Diemen; C Karga; JAM Beliën; B Carvalho; AA Geldof; GA Meijer; OS Hoekstra; RJA Fijneman

VU University Medical Center, Amsterdam, Netherlands

INTRODUCTION: Approximately half of all colorectal cancer (CRC) patients die as a consequence of metastases. Hemihepatectomy is the only curative treatment available for patients with CRC liver metastases (CRCLM), patient eligibility is based on established prognostic clinicopathological variables. Futile surgery has been reduced by patient selection using 18FDG positron emission tomography (PET) molecular imaging, however, 70% of patients still die within 5 years indicating that better prognostic markers are needed. We recently demonstrated that aurora kinase A (AURKA) protein expression drives tumour progression and is associated with disease recurrence in stage III CRC patients. This study aimed to investigate the prognostic value of AURKA protein expression in liver metastases of CRC patients who underwent hemihepatectomy with curative intent.

METHODS: Tissue microarrays (TMAs) were generated from formalin-fixed paraffin-embedded CRCLM of 507 patients who underwent hemihepatectomy in the Netherlands between 1990 and 2010. Matched primary CRC tissue was collected of 234 patients. TMAs were stained for AURKA by immunohistochemistry, nuclear expression of neoplastic cells was assessed and subsequently associated with patient overall survival in a training and validation set.

RESULTS: High AURKA expression in CRCLM was associated with poor overall survival (HRR 1.68; 95%CI 1.04-2.73; P=.03) independent of established prognostic clinicopathological variables (HRR 1.77; 95%CI 1.02-3.08; P=.04). Furthermore, AURKA expression in liver metastases was correlated to its expression in corresponding primary CRC (P=.0002).

CONCLUSION: AURKA protein expression in CRCLM is a molecular biomarker with prognostic value that may aid selection of patients eligible for hemihepatectomy.

P66

Review of Clinico-pathologic Features of Intestinal Metaplasia in Gastric Biopsies of Patients in a Tertiary Health Centre in Nigeria.

© OO Olaofe¹; AO Komolafe¹; DO Sabageh²

¹Obafemi Awolowo University Teaching Hospital, Ile-Ife, Nigeria;

²LAUTECH, Ogbomoso, Nigeria

Purpose of the study: The aim of our study was to review the age, sex and histologic features of cases of intestinal metaplasia in gastric biopsies and to relate the mean age of intestinal type of gastric metaplasia to the known mean age of infiltrating gastric adenocarcinoma earlier reported in this centre.

Methods: A five-year retrospective study of all gastric biopsies with features of intestinal metaplasia reported in the department of Morbid Anatomy and Forensic Medicine, Obafemi Awolowo University Teaching Hospitals Complex, Ile-Ife Nigeria from January 2006 to December 2010 was done. All cases with evidence of dysplasia were excluded from the study.

Summary of results: A total of 165 cases of intestinal metaplasia were seen in the study period. This accounted for 21.3% of all cases. The mean age was 50.3 years (Range of 10 to 100 years). Males accounted for 83 while females accounted for 82 cases. There was no significant difference in the mean age of the sexes (t-test of equality of means, P=0.217) or the type of metaplasia. The type of metaplasia was not associated with the age groups (Chi-square test, P=0.934), sex (P=0.325), severity of chronicity (P=0.274), degree of atrophy (P=0.331) or activity (P=0.472). The difference between the mean age at diagnosis of intestinal metaplasia and intestinal type of gastric cancer is 5 years.

Conclusion: The clinicopathologic features of complete and incomplete intestinal metaplasia do not differ significantly. It probably takes not less than 5 years for a malignant transformation of intestinal metaplasia of the gastric mucosa. Our result may suggest the need for more vigorous and earlier screening.

P68

Structural Genomic Rearrangements in Colorectal Cancer

© E van den Broek¹; JC Haan¹; B Carvalho¹; MA van de Wiel¹; ID Nagtegaal²; CJA Punt²; B Ylstra¹; GA Meijer¹; RJA Fijneman¹

¹VU University Medical Center, Amsterdam, Netherlands; ²UMC Radboud, Nijmegen, Netherlands

Development of colorectal cancer (CRC) is accompanied by genomic alterations that drive tumour initiation and progression. Approximately 85% of all CRCs exhibit chromosomal instability, resulting in gains and losses of relatively large chromosome segments. Besides these quantitative changes in DNA copy number, evidence is emerging that qualitative aberrations such as structural genomic rearrangements that may lead to gene fusions play a significant role in development of several epithelial cancers as well. This phenomenon has long been established for haematological malignancies and may also be essential in CRC. Molecular characterization of structural rearrangements is expected to yield new biomarkers and clinical applications for CRC. The aim of this project is to identify somatic structural genomic rearrangements in CRC.

The prevalence of recurring breakpoints was determined based on array Comparative Genomic Hybridization (CGH) data (180k) from 356 advanced CRC samples and 13 CRC cell lines. Statistical analysis was used in order to assess which breakpoints are non-random. Recurring breakpoints were merged per gene and cluster analysis was used to identify combinations of breakpoints that were present in multiple tumour samples.

In total, approximately 800 recurring breakpoints were identified. The frequency of recurrent breakpoints was detected in up to 25% of CRC samples. Cluster analysis indicates combinations of breakpoint regions. A substantial part of the involved genes overlap with rearranged genes published by AJ Bass et al. (Nature Genetics 2011), such as MACROD2.

We were able to pinpoint commonly recurring breakpoint regions, making use of CGH data from a large cohort of CRC samples. The frequencies observed are conform recent findings for CRC and other types of epithelial cancers. At present we aim to confirm identification of gene fusions by means of Next Generation Sequencing analysis.

P69

Proteome Profiling of Interstitial Fluids from Human Colon Cancer Tissue Reveals Novel Candidate Biomarkers for Early Diagnosis

© M de Wit; H Kant; SR Piersma; TV Pham; S Mongera; MPA van Berkel; E Boven; GA Meijer; CR Jimenez; RJA Fijneman
VU University Medical Center, Amsterdam, Netherlands

Purpose of the study: Detection of CRC at an early stage of disease is a realistic approach to reduce CRC mortality rates. Currently available non-invasive CRC screening tests leave room for improvement, for which novel biomarkers are urgently needed. The aim of this study is to identify novel protein biomarkers that can be used for development of a blood-based or stool-based screening test for early diagnosis of CRC.

Methods: Tumour "interstitial fluids" (IF's) are a rich source of tumour-derived proteins comprising proteins that are secreted, shed by membrane vesicles (exosomes), or externalised due to cell death. Fresh human colon carcinoma tissue and matched normal colon tissue samples were obtained from four patients; tissues were incubated in PBS at 37°C for one hour. These IF's were subjected to in-depth proteome profiling by a GeLC-MS/MS workflow. Quantitative comparisons were based on label-free spectral counting and p-values were calculated using a beta-binomial test.

Results: In total 2703 proteins were identified in the IF's of four patient-matched normal colon and CRC tissues. Of these, 409 proteins were significantly ($p < 0.05$) more secreted by colon carcinoma samples than by controls. The most promising candidate biomarkers were selected based on several criteria, e.g. 5-fold more present in tumour IF's and presence in a CRC cell line proteomic dataset, leading to 64 candidate biomarkers. These include several proteins that have been proposed in literature as markers for (stool-based) CRC screening such as minichromosome maintenance (MCM) proteins.

Conclusions: We conclude that IF proteome profiling of human colon carcinoma tissue is a powerful strategy to discover novel candidate biomarkers for CRC screening. We identified 64 candidate biomarkers that could potentially be used for development of a blood- or stool-based screening test for early diagnosis of CRC. These await further validation studies.

P70

Identification of Putative Oncogenes Located at 13q Involved in Colorectal Adenoma to Carcinoma Progression

© FLM de Groen; O Krijgsman; L Vriend; M Tijssen; RDM Steenbergen; B Carvalho; GA Meijer

VU University Medical Center, Department of Pathology, Amsterdam, Netherlands

Introduction: Colorectal cancer (CRC) is a major health concern worldwide. While pre-malignant lesions, adenomas, can easily be detected on colonoscopy, most of these have a low risk of progression to carcinoma. In order to identify which adenomas are at risk of becoming malignant more knowledge is required on the biology of CRC. We previously showed that gain on chromosome 13q was associated with progression from adenoma to carcinoma. Additionally, combining whole genome expression data with copy number dosage resulted in the identification of 36 genes on 13q of which overexpression was linked to a copy number gain. The functional relevance of these gene alterations however remains to be proven.

Aim: We aim to determine whether genes located on the 13q amplicon are functionally involved in CRC.

Methods: Based on the highest levels of overexpression in carcinomas versus adenomas and literature data we selected six genes for further analysis. Using qRT-PCR and immunohistochemistry gene expression was determined on a pool of adenomas ($n=25$) and carcinomas ($n=23$) in order to validate microarray data. For functional analysis candidate genes were silenced in CRC cell lines using RNAi.

Results: By qRT-PCR, two of the selected genes showed significant overexpression at RNA level in carcinomas compared to adenomas linked to 13q gain. Additionally, we found increased protein expression in carcinomas compared to adenomas. For one candidate gene we found by loss-of-function assays an effect on several cancer-related processes, namely viability, invasion and migration.

Conclusions: We identified two genes at the 13q amplicon of which significant overexpression in carcinoma versus adenoma was linked to 13q gain. For one candidate gene we found functional evidence for a role in CRC. We hypothesize that these genes may provide novel targets for early diagnosis.

P71

Analysis of BRAF Gene Mutation and MLH1 Promoter Methylation in MSI-H Colorectal Carcinomas with Loss of MLH1 Protein Expression

© R Gafá; L Ulazzi; I Maestri; R Mazzoni; G Querzoli; G Lanza
Azienda Ospedaliero-Universitaria di Ferrara, Ferrara, Italy

Purpose of the study. Hereditary and sporadic colorectal carcinomas (CRCs) with deficit of DNA mismatch repair (MMR-D) should be identified in all patients to ensure accurate treatment and risk assessment for relatives. Almost all MMR-D CRCs can be detected by microsatellite instability (MSI) and immunohistochemical testing. Analysis of MLH1 promoter methylation and evaluation of BRAF gene mutational status can help to differentiate hereditary from sporadic MSI-H MLH1-negative colorectal carcinomas. **Methods.** The study included a consecutive series of 2248 CRCs surgically resected from January 2004 to March 2012. Immunohistochemical analysis of MLH1, MSH2, MSH6 protein was performed in all tumours, PMS2 protein only in selected cases. MSI status was determined by a fluorescent PCR method using the Bethesda panel markers plus BAT40; tumours were classified as MSI-H, MSI-L and MSS according to the guidelines of Bethesda. In MMR-D tumours, analysis of MLH1 promoter methylation was assessed by methylation specific PCR and evaluation of V600E BRAF mutation was investigated by direct DNA sequencing.

Summary of results. Deficit of MMR was observed in 332 tumours (14.7%). Most MMR-D tumours showed loss of MLH1 expression (272/332). V600E BRAF mutation was observed in 118/174 MLH1-negative MMR-D tumours and in only 1/42 MLH1-positive MMR-D cancers. MLH1 methylation was detected in 208/235 MMR-D MLH1-negative carcinomas and in 2/50 MMR-D MLH1-positive carcinomas. BRAF mutation was identified in 115/150 MLH1-negative tumours showing MLH1 methylation and only in 3 MLH1-negative tumours without MLH1 methylation.

Conclusions. Our study indicate that MLH1 methylation and BRAF mutation occur frequently in MMR-D CRCs, are closely associated and may be used to identify CRC patients with Lynch syndrome.

P72

The Role of Focal Adhesion Kinase (FAK) in Response to Anti-EGFR Therapy in KRAS Wild-Type Colorectal Cancers

© B Carvalho; M Tijssen; FLM de Groen; C Postma; GA Meijer
Dept Pathology, VU University Medical Center, Amsterdam, Netherlands

Background: KRAS mutation status in colorectal cancer (CRC) is a negative predictive marker for response to anti-EGFR therapy. However, response rates in wild-type KRAS CRC patients are still low, indicating that other factors influence the response to EGFR inhibitors. We recently showed that wild-type KRAS CRCs present heterogeneity at the DNA copy number level and that copy number gain of FAK (focal adhesion kinase), mapping at 8q24.3, leads to its overexpression (unpublished results). FAK, or PTK2 (protein tyrosine kinase 2), is a cytoplasmic tyrosine kinase identified as a key mediator of signalling by integrins. The RAS/RAF/MAPK signalling pathway is one of the pathways that can be triggered by FAK. We hypothesized that wild-type KRAS CRC cells, where FAK is amplified and overexpressed, would be resistant to treatment with EGFR inhibitors, as the downstream RAS/RAF/MAPK pathway would be activated. **Aim:** To functionally test the role of FAK in wild-type KRAS CRC cell lines, after anti-EGFR therapy. **Methods:** Two KRAS wild-type CRC cell lines (Colo320 and Caco2) were selected according to copy number aberrations of the FAK locus (one with amplification and one without). The expression of FAK was evaluated by qRT-PCR. FAK expression was knockdown by shRNA in Colo320. Caco-2, Colo320 and Colo320_FAKkd were treated with EGFR inhibitors and differences in drug sensitivity between cell lines were evaluated. **Results:** The cell line Colo320 with FAK amplification did not show less sensitivity to EGFR inhibitors as hypothesized then the cell line without amplification ($IC_{50} = 5-10 \mu M$ in Colo320 compared to approximately $20 \mu M$ in Caco2). In addition, no change in sensitivity to anti-EGFR treatment was observed in Colo320 after knocking down FAK expression. **Conclusion:** No clear role for FAK amplification and overexpression in the resistance to anti-EGFR therapy could be demonstrated. Work supported by a Path Soc grant.

P73

No Evidence of a Chemotherapy Induced Immune Cell Response in Oesophageal Cancer Tissue – A Pilot Study in Tissue Microarrays Using Immunohistochemistry and Automated Image Analysis

© AK Aziz¹; A Wright¹; D Treanor¹; SP Mehta²; LC Ward¹; HI Grabsch¹

¹Leeds Institute of Molecular Medicine, University of Leeds, Leeds, United Kingdom; ²Department of Upper Gastrointestinal Surgery, St. James's Institute of Oncology, Leeds, United Kingdom

Background: It has been suggested recently, that cytotoxic chemotherapy may induce an anti-cancer immune cell response which may contribute to tumour regression. The impact of neoadjuvant chemotherapy on tumour-infiltrating white blood cells (TiWBCs) has not been investigated in detail in oesophageal cancer (OeC).

Methods: Tissue microarrays were constructed from OeC resection specimens from patients treated with cisplatin/5-fluorouracil (5-FU) chemotherapy followed by surgery (CS-OeC, n=68) or surgery alone (S-OeC, n=93). Neutrophils (CD66b), macrophages (CD68), B cells (CD20) and T cells (CD3, CD8) were identified by immunohistochemistry and quantified by automated image analysis. The mean percentage of immunopositive pixels/tumour core per case was used for analyses. The percentage of TiWBCs were compared between S-OeC and CS-OeC and related to clinicopathological variables including survival.

Results: There was no significant difference in the percentage of CD66b+, CD68+, CD20+, CD3+ or CD8+ pixels/case between CS-OeC and S-OeC (all p values > 0.05). The most abundant immune cell types were CD8+ T cells in both groups. All immune cell types except CD66b+ cells were more abundant in adenocarcinoma compared to squamous cancer in S-OeC but not in CS-OeC (all p values < 0.05). None of the TiWBCs subtypes was related to pT, pN or prognosis neither in S-OeC nor in CS-OeC.

Conclusion: Our study demonstrated that cisplatin/5-FU based chemotherapy does not promote an immune response in the tumour tissue in OeC which is in contrast to a very small previous study in OeC after cisplatin/5-FU and to studies after anthracyclin and taxane chemotherapy in other tumour types. Absence of a relationship between immune cell infiltration and histological subtype in CS-OeC could indicate that the immune response is not simply related to histological subtype. The results from this pilot study require validation in a larger sample set.

P74

Intrahepatic Lymphatic Invasion as a Prognostic Factor for Long-term Survival in Patients with a Solitary Colorectal Liver Metastasis

© N Knijn; J de Ridder; JH de Wilt; ID Nagtegaal

Radboud University Nijmegen Medical Centre, Nijmegen, Netherlands

Purpose of the study: Intrahepatic spread might be of importance in the prognosis of patients after liver metastasectomy. We evaluated the impact of vascular, lymphatic, bile duct and perineural invasion of colorectal liver metastases on overall survival in patients who underwent surgery for a solitary colorectal hepatic metastasis.

Methods: A clinico-pathological study was conducted in 128 patients who underwent hepatic resection for a solitary colorectal liver metastasis between 1992 and 2010. None of the patients received neo-adjuvant chemotherapy. Intrahepatic spread was analyzed using immunohistochemistry (CD31, D240, CK7 and S100 for vascular, lymphatic, bile duct and perineural invasion, respectively). Survival was calculated using Kaplan Meier curves and log-rank tests.

Summary of results: The median overall survival was 56.7 months, with a median follow-up of 40 months (range 0-232 months). Vascular invasion was present in 47 patients (36.7%), lymphatic invasion in 34 patients (26.6%), bile duct invasion in 12 patients (9.4%), perineural invasion in 13 patients (10.2%). The presence of lymphatic invasion was associated with decreased survival. Lymphatic invasion resulted in a median overall survival of 41.9 months versus 61.0 months (p=0.018) in patients without lymphatic invasion. In a multifactorial analysis with established prognostic factors, lymphatic invasion remained a strong prognostic factor.

Conclusion: Intrahepatic lymphatic invasion is an important prognostic factor after liver metastasectomy.

P75

Six Cases of Atypical Appearances in Microscopic Colitis

© JB King; E Wesley; P Sarsfield; I Chandler

Royal Devon and Exeter NHS Foundation Trust, Exeter, United Kingdom

Microscopic colitis is characterised by a normal endoscopy with microscopic features including increased intraepithelial lymphocytes in lymphocytic colitis and a thickened subepithelial collagen layer exceeding 10 µm with mucosal inflammation in collagenous colitis.

We present 6 cases, 2 female and 4 male with an age range of 51-92 years. Five were diagnosed with collagenous colitis, and one was diagnosed with lymphocytic colitis. All showed atypical microscopic features with acute inflammation in the form of cryptitis, crypt abscesses, or the presence of neutrophils within the lamina propria and the epithelium. Three cases also had atypical macroscopic features with total colitis seen at endoscopy, suggestive of a diagnosis of inflammatory bowel disease.

The use of a non-steroidal anti-inflammatory drug may have been the culprit in one of the cases, but there is no other obvious cause in the remaining cases. There is mounting evidence from case reports that microscopic colitis and inflammatory bowel disease are part of a spectrum of abnormal host reactions to known or unknown stimuli. The cases discussed may be intermediate examples of this spectrum.

P76

Novel Candidate Protein Biomarkers for Colorectal Cancer Screening

LJW Bosch¹; M de Wit²; © AC Hiemstra¹; G Oudgenoeg²; SR Piersma²; TV Pham²; S Mongera¹; JS Terhaar sive Droste³; FA Oort³; ST van Turenhout³; I Ben Larbi³; CJJ Mulder³; B Carvalho¹; CR Jimenez²; RJA Fijneman¹; GA Meijer¹

¹VU University Medical Center, Dept. of Pathology, Amsterdam, Netherlands; ²VU University Medical Center, Dept. of Medical Oncology, Amsterdam, Netherlands; ³VU University Medical Center, Dept. of Gastroenterology and Hepatology, Amsterdam, Netherlands

Purpose of the study Colorectal Cancer (CRC) screening can save many lives. Tumour-specific biomarkers have the potential to improve the performance of the widely used fecal immunochemical test (FIT), but so far no protein-based fecal test has proved better. The aim of the present study was to identify tumour-specific protein biomarkers for the early detection of CRC, by applying in-depth proteomics to stool samples from CRC patients and healthy controls.

Methods Stool samples were obtained from 10 subjects with negative colonoscopy and from 12 CRC patients. Proteins were analyzed by in-depth proteomics using gel electrophoresis and nano Liquid Chromatography coupled to tandem mass spectrometry (nano LC-MS/MS). Human proteins were analyzed by hierarchical cluster analysis and visualized in a heat map. As a verification step, an independent stool sample set from 20 subjects were pooled into four groups, including controls (n=5), patients with non-advanced adenoma (n=5), advanced adenoma (n=5) and CRC (n=5) and analyzed by nanoLC-MS/MS.

Summary of results In total 830 proteins were identified of which 134 proteins were significantly enriched in CRC. Unsupervised hierarchical cluster analysis revealed two clusters. One cluster contained nine CRC stool samples, the other cluster contained all ten control stool samples together with three CRC stool samples. From the 134 human proteins significantly enriched in CRC stool samples, 65(59%) were identified in the verification experiment, including 51 proteins that were also detected in stool samples from advanced adenomas.

Conclusions Proteome profiling on stool revealed 134 proteins significantly enriched in CRC compared to control stool samples. These proteins contain promising biomarkers for early detection of CRC. Validation of candidate markers in an independent series of stool samples by SRM-MS is in process.

P77

Pre-operative Neo-adjuvant Therapy is Associated with a Reduced Yield of Lymph Nodes from Colorectal Cancer Resection Specimens.

© W Mifsud; MJ Arends

Addenbrooke's Hospital, Cambridge, United Kingdom

The number of lymph nodes involved by metastatic tumour in colorectal cancer resection specimens is a fundamental variable in tumour staging and prognostication. The total yield of lymph nodes from colorectal cancer resection specimens affects the measured number of tumour-positive lymph nodes and is also independently associated with survival. Lymph node yields are however subject to variation between and within different institutions and it is important to recognise those factors that may affect them.

We retrospectively studied data from 1642 successive colorectal cancer resections received in our department between January 2004 and June 2012 and asked if those cases in which patients had received pre-operative adjuvant therapy yielded fewer lymph nodes than those in which patients had not. We also tested whether lymph node yield was affected by other variables, such as laparoscopic vs. open surgery, specimen dissection by a trainee pathologist vs. a consultant pathologist and, for rectal tumours, the plane of surgical excision.

Our results show a significantly lower lymph node yield in those cases where adjuvant therapy had been given before surgery when compared to those cases where it had not been given (mean lymph node yields were 13.8 and 17.03 respectively, $p=2e-08$). We did not find a significant effect on lymph node yield by any of the other variables that we studied.

We have demonstrated that pre-operative adjuvant therapy is associated with significantly lower lymph node yields from colorectal cancer resection specimens. The impact of this reduction on tumour staging and prognosis remains to be determined.

P78

Differential Expression of Sonic Hedgehog in Human Hepatocellular Carcinoma and Cholangiocellular Carcinoma

R Albahrani; Y Abuetaab; © C Sergi

Department of Lab. Medicine and Pathology, University of Alberta Hospital, Edmonton, Canada

Background and Aim: Hepatocellular carcinoma (HCC) and cholangiocellular carcinoma (CCA) are two primary liver malignancies. The molecular mechanism underlying in both HCC and CCA development are still poorly understood. Sonic hedgehog (Shh) gene expression plays an essential role during mammalian development, i.e. promoting organ growth, tissue differentiation, and cell polarity. The up-regulation of Shh has been identified in different cancers, including as colorectal, esophageal and gastric cancer due to loss of function of tumour suppressor gene patched (Ptch) or overexpression of the oncogene smoothened. Our aim was to investigate the expression of Shh protein in HCC and CCA.

Material and Methods: We investigated 41 malignant tumours of the liver, including 22 HCC and 19 CCA, and 10 normal fetal liver tissues by immunohistochemistry using a polyclonal antibody against Shh using the Avidin-Biotin Complex method. We also investigated the expression of Shh protein in two HCC cell lines HepG2 and Huh7 and three CCA cell lines OZ, HuCCT1 and Huh28. Results: We found an expression of Shh in 63.63% of HCC and 100% of CCA by immunohistochemistry. We found that both of HCC and CCA cell lines showed an expression of Shh protein.

Conclusions: These initial results showed significant overexpression of Shh in liver malignancies, which suggest that Shh may have a crucial role in liver carcinogenesis. Additional studies involving Shh cell signaling may address this pathway in the future as promising target.

P79

Mitochondrial Genomic and Biochemical Analysis in Cholangiocellular Carcinoma Cell Lines

WB Bahitham¹; FB Bamforth¹; BS Stone²; AC Chan³; SN Nagamori⁴; AM Mason⁵; © CS Sergi⁶

¹*Department of Laboratory Medicine and Pathology, University of Alberta, Edmonton, Canada;* ²*Benaroya Research Institute, Seattle, United States;* ³*Department of Genetics, University of Alberta, Edmonton, Canada;* ⁴*National Institute of Infection Disease, Tokyo, Japan;* ⁵*Department of Medicine, University of Alberta, Edmonton, Canada;* ⁶*Department of Pediatrics and Department of Laboratory Medicine and Pathology, University of Alberta, Edmonton, Canada*

Objectives: Cholangiocellular carcinoma (CCA) is the second most common hepatic malignancy, but carcinogenesis is poorly understood. Somatic mitochondrial DNA (mtDNA) mutations have been demonstrated in a variety of human cancers. However, no study has previously investigated mitochondria and its genome alterations in CCA. **Methods:** MitoChip (Affymetrix) resequencing was performed on DNA obtained from 3 CCA and a Papova-immortalized normal hepatocyte cell line (THLE-3). Furthermore, real time quantitative PCR, western blot analysis, electron microscopy, confocal laser microscopy and metabolic assays including L-Lactate and NAD⁺/NADH assays were used to identify mtDNA copy number, oxidative phosphorylation (OXPHOS) content, morphological alterations, mitochondrial membrane potential measurements and metabolic differences, respectively. **Results:** Among 106 mtDNA alterations observed in the 3 CCA (HuCCT1, Huh-28 and OZ) cell lines, 34 were non-synonymous coding region alterations that resulted in an amino acid change. Thirty-nine of these alterations were synonymous and 33 of them were involved in non-coding, including ribosomal RNA (rRNA) and transfer RNA (tRNA). Five in HuCCT1 and four in Huh-28 heteroplasmic alterations were found to be novel. Furthermore, mtDNA copy number was significantly decreased in all CCA cell lines compared with normal hepatocyte. Moreover, there was a significant decrease of complexes I and III associated with morphological alterations and depolarization of mitochondria $\Delta\Psi_m$ in CCA. Metabolic assays including L-Lactate and NAD⁺/NADH assays were significantly increased in CCA lines compared to normal hepatocytes. **Conclusions:** Our findings suggest that mtDNA alterations are common in cholangiocarcinoma. An impairment of the oncogenic mitochondria may be an important event during the carcinogenesis of CCA.

P80

Detection of Viral Integration in Hepatitis C Virus Related Hepatocellular Cancer Using Next Generation Sequencing

© W Fateen¹; S Berri²; H Wood²; J Morgan³; G Taylor³; P Quirke¹

¹*Section of Pathology and Tumour Biology, Leeds Institute of Molecular Medicine, Leeds, United Kingdom;* ²*Section of Pre-Cancer Genomics, Leeds Institute of Molecular Medicine, Leeds, United Kingdom;* ³*Section of Translational Genomics, Leeds Institute of Molecular Medicine, Leeds, UK, Leeds, United Kingdom*

Purpose of the study:

Hepatitis C virus (HCV) is the most common cause of hepatocellular cancer (HCC) in the western world. HCV is an RNA virus that does not integrate with human DNA and so the oncogenic mechanisms of HCV remain unclear.

Next generation sequencing (NGS) provides a flexible platform and generates large amounts of data at a relatively small time and constantly reducing costs.

The role of viral infection is well established in the etiology of a wide range of tumors. In this study we investigate DNA of HCV driven HCC for the possibility of integration of all known viral genomes.

Methods:

Bar coded DNA libraries from 41 samples of various stages of development of HCC were sequenced in parallel. Using NGS, one to two million 74bp reads per genome were generated. The reads were aligned to all known viral genomes downloaded from the National Center for Biotechnology Information using Burrows-Wheeler Aligner (BWA). Reads with mapping scores of < 37 were discarded.

Basic Local Alignment Search Tool (BLAST) was used to test if the sequences that aligned to viral genomes belonged to the human genome or any other viruses apart from the identified virus. Only those reads were the BWA alignment matched the leading BLAST hit were considered.

Summary of results:

HCC test samples mapped to unique sequences from Human Herpes Virus 6 (6/41) and Human Adenovirus (2/41).

Conclusion:

DNA from HCV driven HCC was searched for all viral genome sequences only Human Herpes 6 and Human Adenovirus were found in a small number of cases. Further studies are needed to understand their relation to HCV hepatocarcinogenesis.

P81

Glutathione S-transferase M1-null genotype as risk factor for SOS in oxaliplatin-treated patients with metastatic colorectal cancer

© CPH Vreuls¹; SWM Olde Damink¹; GH Koek¹; A Winstanley²; E Wisse¹; RHE Cloots¹; MAJ van den Broek¹; CHC Dejong¹; FT Bosman³; A Driessen¹

¹Maastricht University Medical Centre, Maastricht, Netherlands; ²Royal Free Hospital, University College London, London, United Kingdom; ³Erasmus University Medical Center, Rotterdam, Netherlands

Background: Oxaliplatin is used as neo-adjuvant therapy in hepatic colorectal carcinoma metastasis. This treatment has significant side effects, as oxaliplatin is toxic to the sinusoidal endothelial cells and can induce sinusoidal obstruction syndrome (SOS), which is related to decreased overall survival. Glutathione plays an important role in the defence system, catalyzed by glutathione S-transferase (GST), including two non-enzyme producing polymorphisms (GSTM1-null and GSTT1-null). We hypothesize that patients with a non-enzyme producing polymorphisms have a higher risk of developing toxic injury due to oxaliplatin.

Methods: In the nontumour-bearing liver the presence of SOS was studied histopathologically. The genotype was determined by a semi-nested polymerase chain reaction.

Results: Thirty-two of the 55 (58%) patients showed SOS lesions, consisting of 27% mild, 22% moderate and 9% severe lesions. The GSTM1-null genotype was present in 25 of the 55 (46%). Multivariate analysis showed that the GSTM1-null genotype significantly correlated with the presence of (moderate-severe) SOS ($p=0.029$).

Conclusion: The GSTM1-null genotype is an independent risk factor for SOS. This finding allows us, in association with other risk factors, to conceive a potential risk profile predicting whether the patient is at risk of developing SOS, before starting oxaliplatin and subsequently might result in adjustment of treatment.

P82

Is it Necessary to Submit Entire Pelvic Lymphadenectomy for Prostate Cancer Specimens for Histology?

© F Alchami; M Varma

University Hospital of Wales, Cardiff, United Kingdom

BACKGROUND: Pelvic lymph node metastasis is a significant adverse prognostic indicator in patients with clinically localised prostate cancer. The RCPATH prostate cancer dataset recommends submitting entire pelvic lymphadenectomy specimens (including fat) for histological examination.

STUDY DESIGN: 278 consecutive prostate cancer patients underwent pelvic lymphadenectomy between 1998 and 2010 in a single centre. Specimens were submitted in total for histological examination. Histology reports of all cases and all slides of positive cases were reviewed to determine the sizes of the positive lymph nodes and tumour deposits.

RESULTS: Metastatic tumour was found 21 (7.6%) of all cases but the positivity rate in more recent (2005-2010) cases was only 2.5% (4/157). All positive cases had tumour deposits within identifiable lymph nodes. Tumour deposits within lymph nodes ranged from <1mm to 31mm (mean 6mm) maximum dimension. The positive lymph nodes ranged from 2mm to 31mm (mean 9mm) maximum dimension. Four of the positive lymph nodes were <5mm diameter but all were associated with a larger (> 5mm) positive lymph node in the same patient.

CONCLUSION: The positivity rate in contemporary cases is very low and all positive cases would have been identified by submitting only firm areas >5mm diameter. It is not necessary to embed all the fat to identify lymph node positive cases in patients undergoing pelvic lymphadenectomy for prostate cancer.

P83

Does Human Papilloma Virus Have a Role in Urinary Bladder Carcinoma of Egyptian Patients?

© MIH Shaban¹; MMA Abd el Wahed¹; KA Forschergruppe²

¹Faculty of Medicine, Shebin el Kom, Egypt; ²Friedrich-Schiller-Universität Jena, Jena, Germany

Background: Bladder cancer is the second most commonly occurring genitourinary cancer in adult. Egypt has the highest bladder cancer rate in the world with local factors most probably responsible for such prevalence. In recent years, viral infections including human papilloma virus (HPV) have been implicated in bladder carcinogenesis. HPV is a small circular DNA virus that infects stratified squamous epithelium and has an established etiological role in tumours of the urogenital tract and anal region. Several previous studies have looked for an association between HPV and bladder cancer development, however, its possible role is still controversial.

Objective: To investigate the possible etiological role of HPV in Egyptian bladder carcinoma.

Patients & Methods: 42 Egyptian patients with bladder carcinoma, 17 cases with cystitis as well as 15 cervical carcinoma cases as a positive control were included in this study. Formalin fixed paraffin embedded tissues were used and stained with; H&E to study histopathologic features, immunohistochemistry for P16 & Ki 67 as well as the tissue processed for PCR for HPV expression.

Result: Only one case of bladder carcinoma showed positivity for HPV with complete negativity in the cystitis group. 52% of bladder carcinoma cases showed P16 expression & 21.4% showed over expression. P16 expression was higher in cases associated with bilharziasis and in transitional carcinoma cases associated with squamous differentiation.

Conclusion: The low prevalence of HPV in this study does not support an etiologic role of HPV in Egyptian bladder carcinogenesis. However, the over expression of P16 in a subset of bladder carcinoma cases could raise a possibility for other HPV type that is not detected by our probe. **Key words:** HPV, P16 and bladder carcinoma.

P84

Differentiation between Prostatic Adenocarcinoma and Urothelial Carcinoma among Egyptian patients: an Immunohistochemical study

MM Abd El-Wahed¹; SA Sakr²; DG El-Sahra²;

© MA Aleskandarany¹

¹Pathology Department, Faculty of Medicine, Menofia University, Shibin El-kom, Menofia, Egypt; ²Histology Department, Faculty of Science, Menofia University, Shibin El-kom, Menofia, Egypt

Background and purpose: Urothelial carcinoma (UC) and prostatic adenocarcinoma (PAC) commonly occur in elderly and share common carcinogenic factors. Simultaneous occurrence of PAC and UC in the prostate is not uncommon. Moreover, invasion of PAC into the urinary bladder wall could also pose a diagnostic challenge with UC and other primary urinary bladder tumors. This study aimed at differentiation between PAC and UC using histochemical and immunohistochemical (IHC) panels.

Methods: This study was carried out on formalin-fixed paraffin-embedded tissue sections representative of 21 PAC cases, 26 UC cases, in addition to nodular prostatic hyperplasia and chronic cystitis, nine cases each, as controls. IHC using specific antibodies against P63, CK7, CK10 and PSA was performed. Moreover, combined alcian blue-PAS (AB-PAS) technique was used to differentiate between neutral and acetic mucosubstances, while the total proteins were detected using mercury bromophenol blue method.

Summary of results: Statistically significant differences were observed between PAC and UC regarding the expression of p63, CK7, and PSA; where 100% of UC cases were p63 and CK7 positive and PSA negative ($p < 0.000$). The CK10 was positive in 52.4% of PAC cases, yet all UC cases negative expression ($p < 0.000$). The incidence of acid mucins was statistically different in UC and PAC ($P < 0.000$), while no significant differences were observed regarding the incidences of neutral mucins ($p=0.242$) and total proteins ($p=0.311$).

Conclusions: p63 and CK7 could be considered as markers of urothelial differentiation. Moreover, the IHC panel of p63, CK7, CK10 and PSA, in addition to the histochemical AB-PAS stain can be used in the differential diagnosis, along with other markers, in morphologically difficult cases particularly in poorly differentiated PAC and high grade urinary bladder UC.

P85

Renal Cell Carcinoma with Ossification – Three Case Reports of this Rare Phenomenon

EL Short¹; © O Kozyar¹; D Griffiths¹; C Leung²; V Trainer²; N Venkatanarasimha²; J Shannon³

¹Department of Histopathology, University Hospital of Wales, Cardiff, United Kingdom; ²Department of Radiology, University Hospital of Wales, Cardiff, United Kingdom; ³Department of Histopathology, Royal Glamorgan Hospital, Pontyclun, United Kingdom

Renal cell carcinoma (RCC) is frequently associated with calcification, but ossification is extremely rare(1). Ossification may have prognostic implications, so it is important that it is identified radiologically and microscopically. We present 3 cases of renal cell carcinoma with ossification: a 52-year-old female who presented with haematuria, a 50-year-old male cadaveric organ donor and a 71-year-old female with an incidental renal mass.

In a review of 2709 renal masses intratumoral calcification was shown to be present in 10.3% of renal cell carcinomas (RCC)(2). Osseous metaplasia is rare but has been reported in clear cell(3,4), chromophobe(5,6), multilocular cystic(7)and papillary(4) RCC.

Although controversial, RCCs with ossification are said to present at an early stage(1) and are therefore associated with a more favourable surgical outcome and better prognosis. The mechanism of ossification is unclear. Hypotheses include metaplastic or reparative responses in either the tumours or the surrounding tissues, the production of bone by tumour cells or the ossification of a pre-existing mucin or calcium deposit(1). Yamasaki et al(8) report that RCC tumour cells can produce bone morphogenetic protein-2 (BMP-2), which induces osteoblastic differentiation of stem cells. They suggest that ossification may result from metaplasia of pluripotent stem cells into osteoblasts by the mechanism of paracrine secretion of BMP-2.

References

- 1.Kefeli M et al. Pathology–Research & Practice 2007 203:749-752
- 2.Daniel W et al. Radiology 1972 103:503-8
- 3.Moriyama H et al. Hinyokika Kyo 2002 48(10):603-5
- 4.Sengoku A, Hazama M, Takeda Z. Hinyokika Kyo 1992 38(3):327-31
- 5.Wu SL, Fishman IJ, Shannon RL. Annals of Diagnostic Pathology 2002 6(4):244-47
- 6.Yokozaki H et al. Japanese Journal of Clinical Oncology 2000 30(2):101-4
- 7.Bloom T et al. Urology 2003: 61(2):462
- 8.Yamasaki M et al. The Journal of Urology 2004 172:475-6

P86

Disseminated BCG Following Intravesical Therapy For Transitional Cell Carcinoma; Report of Two Cases

© L Zakarneh¹; NM Aqel²; N Panoskaltis²

¹Hammersmith Hospital, London, United Kingdom; ²Northwick Park Hospital, London, United Kingdom

Introduction: Intravesical vaccination by BCG has proved to be an effective immunotherapy of superficial transitional cell carcinoma (TCC) of the urinary bladder. It is useful in slowing down of the tumour progression and improves patients' survival. Its side effects include local urinary symptoms and mild general side effects. Serious systemic complications of intravesical BCG immunotherapy are rare. We describe two patients who developed dissemination of BCG following intravesical instillation for the treatment of bladder TCC.

Patients and pathology findings: Two male patients, 70 and 77 years old were diagnosed with low grade TCC of the urinary bladder for which they were treated by intravesical BCG. Three months later, these patients have then developed fever, weight loss and difficult breathing. First patient also developed a picture of ITP with platelets levels of 30/mm³ and second patient was found to be anaemic with Hb level of 10.1g/dl. Examination of their bone marrow aspirates and marrow trephine biopsies was followed and the marrow biopsies contained multiple well formed epithelioid cell granulomas without caseation. ZN stains for AFB were negative. Chest x-ray of the two patients showed lung shadowing suggestive of TB and second patient had a chest CT scan which showed lung nodules consistent with pulmonary TB. A diagnosis of disseminated BCG was established in both patients who were then treated promptly with anti-tuberculous therapy including steroids and have been cured.

Discussion: Incidence of bladder TCC and therefore BCG therapy is on the increase in our population which is getting older and who also would suffer from age-related immunosuppression. Only two case reports of disseminated BCG have been reported in the UK. Cytopenia and BM involvement has not been a feature in these cases. Our findings should alert histopathologists to this upcoming diagnosis which needs to be treated promptly.

P87

Altered MicroRNA Expression Associated with Chromosomal and Epigenetic Changes Contributes to Cervical Carcinogenesis

SM Wilting; PJF Snijders; W Verlaet; A Jaspers; GA Meijer; CJL Meijer; © RDM Steenberg

VU University Medical Center, Amsterdam, Netherlands

MicroRNAs play prominent role in cancer development though little knowledge exists on altered miRNA expression patterns during cervical carcinogenesis and their association with chromosomal and epigenetic changes. Here, miRNA expression profiles of normal cervical squamous epithelium, high-grade precancerous lesions (CIN2-3), squamous cell carcinomas (SCC) were integrated with previously generated chromosomal profiles of the same samples. In addition, DNA methylation was assessed in downregulated miRNAs located within a CpG island.

Significantly differential expression during cervical SCC development was observed for 106 miRNAs. Altered expression of hsa-miR-9 (1q23.2), hsa-miR-15b (3q25.32), hsa-miR-28-5p (3q27.3), hsa-miR-100 and hsa-miR-125b (both 11q24.1) was directly linked to frequent chromosomal alterations (Wilting et al., 2012). For 3 miRNAs, hsa-miR-149, hsa-miR-203 and hsa-miR-375, downregulated expression was correlated to increased promoter methylation. Methylation levels of hsa-miR-203 and hsa-miR-375 were significantly increased in CIN3 lesions and SCCs compared to normal cervical epithelium, whereas hsa-miR-149 methylation was only increased in SCCs.

For hsa-miR-9, showing increased expression linked to a chromosomal gain as well as hsa-miR-203 and hsa-miR-375, both silenced by DNA methylation, a respectively novel oncogenic and tumour suppressive role in cervical carcinogenesis was shown, as they affected both cell viability and anchorage independent growth of cervical cancer cells in vitro.

In conclusion, altered expression of miRNAs in cervical (pre)cancers is only partly associated with chromosomal alterations and epigenetic changes. Altered expression of hsa-miR-9, hsa-miR-203, and hsa-miR-375 associated with a chromosomal gain or DNA methylation respectively, was shown to be functionally relevant, underlining the importance of deregulated miRNA expression in cervical carcinogenesis.

P88

Fallopian Tube Intraluminal Tumour Spread from Non-invasive Precursor Lesions: A Novel Metastatic Route in Early Pelvic Carcinogenesis

© JG Bijron¹; CA Seldenrijk²; RP Zweemer¹; JG Lange²; RHM Verheijen¹; PJ van Diest¹

¹University Medical Centre Utrecht, Utrecht, Netherlands; ²Saint Antonius Hospital, Nieuwegein, Netherlands

Purpose: Pelvic serous carcinoma is usually advanced stage at diagnosis, indicating that abdominal spread occurs early in carcinogenesis. Recent discovery of a precursor sequence in the Fallopian tube, culminating in serous tubal intraepithelial carcinoma (STIC) provides an opportunity to study early disease events. This study aims to explore novel metastatic routes in STICs.

Patients and methods: A BRCA1 mutation carrier (patient A) that presented with a STIC and tubal intraluminal shed tumour cells upon prophylactic bilateral salpingo-oophorectomy (PBSO) instigated scrutiny of an additional 23 women who underwent a PBSO and 40 patients with pelvic serous carcinoma involving the tubes.

Results: Complete serial sectioning of tubes and ovaries of patient A did not reveal invasive carcinoma, but subsequent staging surgery showed disseminated abdominal disease. STIC, intraluminal tumour cells and abdominal metastases displayed an identical immunohistochemical profile (p53+/WT1+/PAX8+/PAX2-) and TP53 mutation. In sixteen serous carcinoma patients (40%) tubal intraluminal tumour cells were found, compared to none in the PBSO group.

Conclusion: This is the first description of a STIC, which plausibly metastasized without the presence of invasion through intraluminal shedding of malignant surface epithelial cells in the tube and subsequently spread through the peritoneal cavity. These findings warrant a reconsideration of the malignant potential of STICs and indicate that intraluminal shedding could be a risk factor for early intraperitoneal metastasis. Though rare in the absence of invasive cancer, we show that shed intraluminal tumour cells in the Fallopian tubes from serous carcinoma cases are common and a likely route of abdominal spread.

P89

Proportion of HPV 16-associated CIN2+ Lesions in Non-attendees of the Cervical Screening Programme is Constant over All Age Groups in Contrast to Regular Screen Responders

© VMJ Verhoef; NJ Veldhuijzen; DAM Heideman; FJ van Kemenade; AT Hesselink; M Gok; PJF Snijders; J Berkhof; CJL Meijer

VU University Medical Center, Amsterdam, Netherlands

Objective: Most CIN2+ lesions detected by screening are HPV 16 associated. The proportion of these HPV 16 associated CIN2+ lesions is higher in younger women than in older women. HPV 16 positive CIN 2+ lesions display the highest progression rate to cervical cancer. Offering self-sampling for hrHPV testing has been shown to be an effective alternative for non-attendees of the screening programme. However, the HPV16 contribution to CIN2+ in these non-screened women is unknown. Here, we genotyped self-sampling detected CIN2+ in non-attendees and compared the HPV genotypes with CIN2+ present in regularly screened women by age.

Methods: Non-attendees of the screening programme (30-60 years), were offered hrHPV self-sampling. HrHPV testing on self-collected samples was done by HC2 and HC2 positive women were subsequently genotyped by GP5+/6+ -PCR using a bead-based xMAP Luminex readout. HrHPV genotype distribution in detected CIN2+ was compared with that of regular screening responders in the same geographical area.

Results: 15,274 out of 52,447 women (29%) responded to HPV self-sampling. CIN2+ yields were significantly higher in the self-sampling group than in the screening group (RR: 1.6; 95%CI: 1.4-1.9). Prevalence of HPV infection in the non-attendees ranged from 16% in women 29-33 years to 5.9% in women 59-63 years, which is higher than in the regular screening responders (i.e. 12% to 2.4%). Interestingly, the relative contribution of HPV16 to CIN2+ (51%) in the non-responders was constant over all age groups. This is in contrast to regular screening responders, where an age-associated decrease of HPV16 in incident CIN2+ lesions was seen.

Conclusion: The constant high contribution of HPV 16 to CIN2+ lesions over all age groups in HPV self-sampling participants among non-attendees, as compared to responders of the screening programme, may explain the increased risk of cervical carcinoma in these non-responder women.

P90

Case Study of a P53 Signature in the Fallopian Tube of a BRCA2 Carrier

© H McCarthy; S Phelan; Z Orosz

University College Hospital Galway, Galway, Ireland

We describe the case of a 52y/o woman who was found to carry a BRCA2 mutation and underwent bilateral mastectomies and subsequent prophylactic hysterectomy with bilateral salpingo-oophorectomy (BSO). Both fallopian tubes and ovaries were grossly normal but were all embedded using the SEE-FIM protocol. Histologically, the distal fimbria showed small foci of mild nuclear hyperchromasia, with loss of ciliation. Immunohistochemistry (IHC) showed strong p53 staining in these areas, without increased Ki-67 expression. A diagnosis of "p53 signature" was made. Up to 40% of women with BRCA mutation will develop serous epithelial ovarian cancer (EOC) without intervention and serous TIC (Tubal Intraepithelial Carcinoma) is identified in up to 8% of women undergoing risk reducing surgery. The term P53 signature is used to describe lesions with no or mild atypia which express p53 in 12+ secretory cells, and has been proposed as a candidate precursor lesion to serous TIC. These lack the severity of atypia and proliferation to warrant a label of TIC. The frequency of p53 signature is controversial with recent studies reporting a detection rate of 71% in the BRCA+ population and 50% in control populations when levelled sections and IHC are used, underscoring the importance of systematic evaluation of tubal epithelium.

P91

Diagnostic Accuracy in Ovarian Cyst Cytology

© KP Lawes; L Brown

Leicester Royal Infirmary, Leicester, United Kingdom

Introduction: In the literature, the diagnostic accuracy of ovarian cyst cytology is variable, with sensitivities from 25-100% and specificities of 90-100%. Current guidelines for ovarian cyst cytology sampling state that it should not be performed in asymptomatic post-menopausal women and only in "highly selected cases" for pre-menopausal women. **Aims:** (1) To establish the proportion of ovarian aspirates where a diagnosis was made, in order to assess the usefulness of cytology alone. (2) To compare the cytological diagnosis to the histological diagnosis, in order to determine accuracy.

Method: 323 ovarian cyst cytology reports over 11 years were examined and assigned to 1 of 6 categories depending on the certainty of diagnosis. The number of cases in each category was used to calculate a percentage. Accompanying histology was sent in 95 of the cases. Where available, the cytological diagnosis was compared to the concurrent or subsequent histological diagnosis. The numbers of concordant, discordant, benign and malignant cases were calculated.

Results and conclusions: A specific or possible cytological diagnosis was made in 38% (87 of 228) of cases where a lone aspirate was taken. Where available, comparison of cytological and histological findings showed that an accurate cytological diagnosis was only made in 29% of cases, with a sensitivity of 29% and specificity of 98%. Of concern, 2 benign cysts were diagnosed as suggestive of at least borderline malignancy on cytology (false positives) and 5 malignancies were not detected by cytology (false negatives). **Recommendations** are that (1) there is no added value in examining ovarian cyst cytology if histology is available, and (2) there is minimal application for ovarian cyst cytology as a diagnosis was only made in approximately one third of cases.

P92

Primary Malignant Mixed Mullerian Tumour (MMMT) Arising in the Fallopian tube: A Rare Case

© L Moore¹; C Geary¹; M Shafi¹; MJ Arends²; A Patterson¹; B Rous¹; M Jimenez-Linan¹

¹Addenbrooke's Hospital, Cambridge, United Kingdom; ²Department of Pathology, University of Cambridge, Cambridge, United Kingdom

INTRODUCTION: Malignant Mixed Mullerian Tumour (MMMT) of the Fallopian tube is a rare high grade tumour. It usually affects post-menopausal women (mean age, 60years). The 5-year survival rate is approximately 15%.

CASE REPORT: A 48-year old female was found to have abnormal glandular cells on a routine cervical cytology sample. The cells were thought to be of non-cervical origin with possible endometrial or ovarian primary sites. Subsequent imaging, hysteroscopy and endometrial biopsy showed no obvious lesions. Following a review at the MDT meeting, a total abdominal hysterectomy and bilateral oopho-salpingectomy were performed. Examination of the resection specimen revealed normal uterus, cervix, both ovaries and the right Fallopian tube. A small area of wall thickening was identified within the distal part of the left Fallopian tube.

HISTOLOGY: Sections of the uterus, entire cervix, ovaries and the right Fallopian tube showed no significant abnormality. However, histological examination of the left Fallopian tube revealed a biphasic tumour with malignant epithelial and stromal components, arising in the background of tubal carcinoma in situ. The epithelial component had serous morphology. The stromal component showed heterologous (rhabdomyosarcomatous) differentiation. The fimbriae and the proximal part of the Fallopian tube were unremarkable.

IMMUNOHISTOCHEMISTRY: The epithelial component of the tumour (invasive and in-situ) was positive for cytokeratin, p53 and WT-1. The stromal component was positive for desmin, myogenin and MyoD1. Actin was negative.

DIAGNOSIS: Primary Malignant Mixed Mullerian Tumour (MMMT) of the Fallopian tube.

DISCUSSION: MMMT of the Fallopian tube is a rare tumour. Differential diagnosis of abnormal (non-cervical) cells on a cervical smear should include endometrial, ovarian and Fallopian tube pathology.

P93

Co-expression of Musashi 2 and HOXA9 in Acute Myeloid Leukaemia

M Back¹; C Keeling²; E Tholouli²; © RJ Byers¹

¹University of Manchester, Manchester, United Kingdom; ²Manchester Royal Infirmary, Manchester, United Kingdom

Acute myeloid leukaemia has a high mortality though specific cytogenetic subtypes have better outcome due to targeted treatment. This has stimulated interest in identifying novel prognostic markers that may help understand underlying biology and enable development of additional targeted therapies. The RNA binding protein MSI2 is a poor prognostic indicator whilst expression of homeobox transcription factor HOXA9 is negatively correlated with survival. Increased HOXA9 expression is thought to drive MSI2 expression, and together promote the proliferation of undifferentiated leukaemic cells. Understanding the relationship of MSI2 and HOXA9 in situ is therefore important for development of new treatments.

The relationship between MSI2 and HOXA9 in situ was investigated using dual immunohistochemistry on 58 patient bone marrow trephines in a tissue microarray. High levels of protein co-localization were correlated with a less differentiated (M1) FAB subtype ($p=0.0448$). Kaplan-Meier survival analysis identified that high levels of both HOXA9 and MSI2 were associated with a shorter survival time ($p=0.0359$). Single protein expression, for either HOXA9 or MSI2, was not significantly associated with survival. HOXA9 protein expression was significantly increased in patients with a good cytogenetic prognosis ($p<0.0001$); this is contrary to previous mRNA studies. The results suggest that HOXA9 and MSI2 act co-operatively to prevent differentiation of cells, leading to a poorly differentiated leukaemic phenotype. Additionally, the differential survival effect of HOXA9 protein and mRNA levels suggest the presence of a negative feedback loop between the two. Overall the results support importance of MSI2 and HOXA9 for outcome in AML, whilst association with poor cytogenetic subtype, which suffers from poor outcome, suggests use as possible novel targets.

This work was supported by a Pathological Society Intercalated BSc grant.

P94

Dissecting the Grey Zone Between Follicular Lymphoma and Nodal Marginal Zone Lymphoma using Morphological and Genetic Features

© O Krijgsman¹; P Gonzalez²; O Balagué Ponz²; M Roemer²; S Slot²; A Broeks²; L Braaf²; R Kerkhoven²; F Bot³; K Groningen⁴; M Beijert⁵; B Ylstra¹; D de Jong¹

¹VU University Medical Center, Amsterdam, Netherlands; ²NKI, Amsterdam, Netherlands; ³HAGA ziekenhuis, Den Haag, Netherlands; ⁴Spaarne Ziekenhuis, Hoofddorp, Netherlands; ⁵UMCG, Groningen, Netherlands

Nodal marginal zone lymphoma (NMZL) is a poorly defined entity in the WHO classification, largely based on criteria by exclusion and diagnosis remains largely subjective. Especially t(14;18) negative FL result in potential diagnostic overlap. Refined classification, however, is essential for adequate prediction of clinical course, prognosis and for selection of focused treatment strategies. Our aim is to dissect the overlapping area between NMZL and FL using morphological and genetic features. Morphologically and immunohistochemically selected FFPE lymphoma biopsy samples ($n=56$) were analyzed on a high-resolution DNA copy number platform (NimbleGen) in four subgroups; NMZL ($n=14$), t(14;18) negative FL (t-FL, $n=12$), localized t(14;18) positive FL (LOC t+ FL, $n=16$) and disseminated t(14;18) positive FL (DIS t+ FL, $n=14$). Gain (or partial gain) of chromosomes 7, 8 and 12 were observed in all classes. The mean number of aberrations in DIS t+ FL was significantly higher than in LOC t+ FL ($p<0.01$) and the majority of specific alterations in LOC t+ FL were also found in disease DIS t+ FL. NMZL was marked by specific gains at 3q with specific amplifications for CBLB, BBX and SLC12A8 and HEG1. T-FL showed a distinctively different overall pattern of large and focal aberrations as compared to the T+ group. Apart from gains common in all classes, also this group was marked by chromosome 3 gains as in NMZL, including specific focal gains.

Classical T+ FL is characterized by a relatively specific spectrum of genetic alterations that are also reflected in early stage disease, supporting the notion that localized disease may indeed represent an early phase of the same process.

So-called T-FL bears genetic alterations that are more alike NMZL, suggesting a relation between these classes. The spectrum of alterations of NMZL is less specific than for FL, however, precluding very strong conclusions.

P95

Atypical Marginal Zone Hyperplasia with Bilateral Tonsillar Involvement, Lambda Light Chain Predominance and CD5 Expression – a Case Report in a 3 year Old Child

G Pitiyage; A Jay; © AD Ramsay

University College London Hospital, London, United Kingdom

Atypical marginal zone hyperplasia (AMZH) is a reactive condition of childhood showing a proliferation of lambda light-chain restricted lymphoid cells in tonsils or appendix.

AMZH was described in 2004 and is a recognised mimic of lymphoma. We report a case of CD5-positive tonsillar AMZH in a 3 year old boy.

The patient presented with bilateral tonsillar swelling and a bilateral tonsillectomy was performed. Macroscopically both tonsils were enlarged with a maximum diameter of 33mm. Histologically both tonsils showed similar features; the normal architecture was maintained and there was a marked expansion of the lymphoid component. The latter consisted of lymphoid follicles with reactive germinal centres and markedly expanded marginal zones. There was extensive infiltration of the tonsillar epithelium by the marginal zone cells, which also showed colonisation of the germinal centres.

Immunohistochemistry showed that these marginal zone cells expressed CD20, bcl-2, IgM and IgD. Bcl-6 showed only weak positivity and CD3, CD10, cyclin-D1 and MUM1 were negative. CD21 highlighted the follicular dendritic cell networks. Of interest is that the marginal zone cells also stained for CD5 and OCT2. As described in literature, the hyperplastic marginal zone cells showed a predominant expression of lambda light chain. PCR analysis showed no evidence of a monoclonal B or T cell expansion.

The reported cases of AMZH showed no recurrence or malignancy, and our patient remains well at 6 monthly follow-up. Although marginal zone lymphoma is rare in children and at native MALT sites such as tonsil or adenoid, pathological recognition of this entity is important to avoid a possible mis-diagnosis of malignancy.

P96

The Utility of Needle Core Biopsies in Lymphoma Diagnosis; A One-year Audit in a Specialist Haematopathology Unit

© N Alrahbi¹; AD Ramsay²

¹The Royal Hospital, Muscat, Oman; ²University College London Hospital, London, United Kingdom

Radiology-guided needle core biopsies are increasingly used for the diagnosis or exclusion of haematological malignancy. To fully assess the diagnostic utility of these specimens, we have carried out a one-year audit of needle core biopsy diagnoses in a specialist haematology unit.

In 2010 the department received a total of 224 needle core biopsies from patients with suspected haematological malignancies. 199 biopsies (89%) were from lymph nodes and 29 (11%) were from extra-nodal sites. Of these biopsies, 202 (90%) provided a definite diagnosis, 17 (8%) were non-diagnostic and 5 (2%) were suspicious but not fully diagnostic of lymphoma. Repeat biopsy was performed in 4 patients (1.8%); 3 of these resulted in a definitive diagnosis of lymphoma and 1 showed no evidence of neoplasm. 14 patients with non-diagnostic biopsies and 4 in the "suspicious" group had no further histological investigations. In 175 biopsies (78%) we were able to make definitive WHO diagnosis of malignant lymphoma. The commonest diagnostic categories were diffuse large B cell lymphoma, follicular lymphoma, and classical Hodgkin lymphoma. Non-lymphoma diagnoses were made in 28 patients (12.5%); in this group the most common findings were non-specific reactive changes and granulomatous lymphadenopathy. We found needle core biopsy to be a valuable tool in the diagnosis of haematological malignancy, with a sensitivity of over 90% and the identification of a specific haematological malignancy in 78% of patients. We conclude that in a specialist haematology unit, with experienced radiologists and pathologists practised in the interpretation of these specimens, needle core biopsy can provide a firm diagnosis in the majority of patients.

P97

Kikuchi's Lymphadenitis Developing in Lymph Nodes Draining Breast Carcinoma; a Study of Three Cases

© L Zakarneh¹; R Salameh²; NM Aqel²; E Nigar²

¹Hammersmith Hospital, London, United Kingdom; ²Northwick Park Hospital, London, United Kingdom

Introduction: Kikuchi's lymphadenitis (KL) is an acute self-limiting febrile illness associated with lymph node enlargement. Only two cases of KL have been described in lymph nodes draining tumours: stomach carcinoma and a malignant fibrous histiocytoma. We describe three novel cases of KL involving axillary lymph nodes draining invasive breast carcinoma.

Materials and Methods: This is a study of three female patients with invasive breast carcinoma aged 31, 51 and 66 years. Breast and axillary lymph nodes biopsies were examined. An Immunocytochemical panel including antibodies to CD20, CD79a, CD68, CD3, CD4, CD8, CD123, CD38, Bcl-2 and MPO was carried out on axillary lymph nodes. SDF-1 and HECA 452 were added to the panel in case 1 and case3, respectively.

Results: Case 1 and 2 had invasive ductal carcinoma while case 3 had invasive lobular carcinoma. Features of KL were seen in the axillary lymph nodes draining the invasive carcinoma in the three cases. These included extensive paracortical infiltration by plasmacytoid monocytes (PMs) undergoing marked apoptosis. PMs stained positive for CD123, CD38 and CD68 and were negative for Bcl-2 and other lymphoid markers. In case 1 and 2, KL and metastatic carcinoma were identified in the same node.

Conclusion: This study documents three cases of KL in axillary lymph nodes draining breast carcinoma. This follows our previous observation of the presence of PMs in lymph nodes draining breast carcinoma. We conclude that KL appears to represent the extreme end of this immunological phenomenon with possible racial and genetic predisposition.

P98

Microbiology in Stillbirths

© RHM Armstrong¹; TL Clark²; CC Platt¹

¹University Hospital's Bristol NHS Foundation Trust, Bristol, United Kingdom; ²University of Bristol, Bristol, United Kingdom

RCPATH 2006 Guidelines for stillbirths suggest carrying out bacteriology on lung and blood and virology for relevant cases.

Between January 2010 and December 2011 (Prior to adopting a local agreement) 1% of our stillbirth cases had blood samples taken for bacteriology and 58% and 62% had lung samples taken for bacteriology and viral PCR respectively. During this period we examined 182 stillbirths (80% 3rd trimester and 20% 2nd trimester).

4% (8) of cases had a funisitis and 25% had a chorioamnionitis (45/181 cases). All funisitis cases had a chorioamnionitis. Microbiology was performed in 69% cases with chorioamnionitis. 16 out of the 45 (36%) chorioamnionitis cases had positive microbiology results, 15 (33%) had negative microbiology results and 14 out of the 45 (31%) chorioamnionitis cases did not have microbiology testing done. 52% with positive bacteriology results had neither funisitis nor chorioamnionitis. 2 out of the 8 funisitis cases had positive microbiology results (Beta haemolytic *Streptococcus* Group B and *Gardnerella*).

Lung PCR was performed in 113 of 182 cases and showed no positive result for CMV, HSV or Parvovirus. On occasions the virology laboratory conducted a wider range of tests which showed one positive adenovirus PCR and one positive EBV PCR.

Bacteriology was positive in 56 instances from 40 cases and cultured the following: *Enterococcus* spp (10), Gram negative bacillus (10), *Enterococcus faecalis* (10), *E.coli* (9), *bacillus* spp (4), Beta haemolytic *streptococcus* Gp B (4), and coagulase neg *Staphylococcus* (2), and one each for *Streptococcus agalatae*, *Pseudomonas putida*, mixed anaerobes, *Klebsiella pneumoniae*, *Staphylococcus haemolyticus*, *Gardnerella* and *Proteus mirabilis*. Clinicopathological Correlation (CPC) was essential in these cases. Conclusion: Stillbirth viral PCR studies are likely to be negative but may be a useful negative. Bacteriology needs CPC.

P99

Placenta Examination, Obesity and Diabetes in Libya – The Case for a Longitudinal Birth Cohort Study

S Murmesh¹; M Mormesh¹; N Vincenzo¹; © C Platt²

¹Al Fairouz Centre for Fertility, Tripoli, Libya; ²University Hospital's Bristol NHS Foundation Trust, Bristol, United Kingdom

In a preliminary study conducted in Tripoli in 2009, Eltobgi identified 73% of 4,000 randomly selected individuals were affected by type-2 DM or were intolerant to glucose. Of these individuals, 70% were obese (BMI >30). Recently, Sheriff suggested the urgent need to create a "Libyan National Diabetic Control Policy". In 2002, according to the WHO, 73% of deaths in Libya were due to chronic diseases. Cardiovascular diseases contributed to 43% of these deaths.

Data collected from patients attending the Al Fairouz Centre for Fertility in Tripoli during the year 2010 provided some supporting data and showed that from a total of 694 new patients asking for fertility treatment, only 134 (19.3%) had a normal BMI and 560 (80.7%) had a raised BMI. The total number of obese patients (BMI ≥30) was 322 (46.4%). The Barker hypothesis says that adverse fetal growth is strongly associated with a number of chronic conditions later in life including coronary heart disease, stroke, diabetes, and hypertension.

A longitudinal birth cohort study including a study of the placenta may help elucidate the search for the fetal origins of disease in the Libyan population. However, until recently the placenta has been little studied in Libya. At the Tripoli Medical Centre (TMC) in 2008, a total number of 10,916 deliveries occurred including 135 twins, 3 triplets and 132 Intrauterine Foetal Deaths (IUID). Only 7 placentas were analysed in the histopathology department. The Alkhadra hospital for the period 2010 and 2011 showed a total of 7,635 deliveries but no placenta was sent to histopathology although there were 306 twin pregnancies, 33 triplets, and 72 IUID.

Conclusion: Libya has a high incidence of conditions that might have their origins in fetal life. Developing capacity for placenta examination as part of a longitudinal birth cohort study may be useful in defining this.

P100

αB-Crystallin Triggers Innate Responses in Preactive Multiple Sclerosis Lesions

L Peferoen¹; M Bsibsi²; J Horssen³; W Gerritsen³; M Kipp⁴; P van der Valk³; J van Noort²; © S Amor³

¹Department of Pathology, VU University Medical Centre, Amsterdam, Netherlands; ²Delta Crystallon, Leiden, Netherlands; ³VUMC, Amsterdam, Netherlands; ⁴Institute of Neuroanatomy, Faculty of Medicine, RWTH Aachen University, Aachen, Germany

Multiple Sclerosis (MS) is a complex chronic neurodegenerative disease of the central nervous system characterized by lesions of inflammation and demyelination. The temporal order of MS lesion development is the active lesion, followed by chronic active lesion in which microglia accumulated at the rim as myelin in the centre is progressively removed. Finally, such a lesion dies out, leaving a scar-like inactive lesion. Still the question remains how MS lesions really start.

Imaging studies of the CNS of MS patients reveal signals in the normal-appearing white matter (NAWM) prior to development of active lesions. These signals do not represent classical MS lesions upon routine histological examination but rather reveal clusters of activated microglia in NAWM indicating early pathological changes, we term 'preactive lesions'.

In the VUmc cohort of MS patients pre-active lesions are seen in the majority of patients irrespective of disease duration, sex or cause of death. No blood-brain-barrier disruption is observed suggesting that intrinsic trigger of innate immune activation leads to lesion formation in the CNS, rather than extrinsic factors crossing a damaged blood-brain barrier.

To examine triggers of microglia activation we have performed pathology studies of preactive lesions. This demonstrated that oligodendrocytes in preactive lesions contain αB-crystallin, a stress induced heat-shock protein. In vitro we demonstrate that αB crystallin induces an immune regulatory activation status of microglia. Microarray studies using the Agilent system have extended this finding revealing novel molecules and pathways associated with immune regulation in the CNS.

Together, these data suggest that αB crystallin accumulation in preactive lesions may be part of a reversible reparative local response and points to a key role for stressed oligodendrocytes in early MS pathogenesis.

P101

Is Histopathology Considered During The Expansion and Remodelling of Surgical Services? Virtual Billing Helped in Recouping the Expenses in Our Experience in the Neuropathology Department.

© F Alchami; GA Lammie

University Hospital of Wales, Cardiff, United Kingdom

Introduction: There was a significant increase in the workload of our neuropathology department on configuration of the regional neurosciences. From June 2009 a sole neurosciences centre was established. As a result there was planned increase in the surgical sessions, but no significant support for the neuropathology department.

Methods: A Telepath search of all neuropathology specimens for the first year of configuration was generated, and a spreadsheet was created to include the name, age, address, specimen type, diagnosis, IHC, cytogenetics. The lab costs were generated for each case. The time needed for reporting was recorded using the Royal College recommendations¹.

Results: There were a total of 300 specimens from 294 patients of which 100 (33%) originated from a different catchment area and were generated by the reconfiguration. There was a steady increase of specimens per month during the interim period from 2 to 17 with an average of 9 cases. The total lab cost was £10740 (estimated to be £8000 during planning). The consolidation plan failed to include the increase in consultant workload. The consultant workload, taking into consideration the complexity of the cases, while applying the Royal College guidance, with added MDT, frozen section implications amounted to 4.5 hours per week. This study did not include the secretarial and autopsy workload generated.

Conclusion: Histopathology is often not considered during the remodelling of surgical specialities and the cost implication predicted is generally less than the real cost. Virtual billing and auditing the workload is essential in creating a business case to recoup the financial implication.

References: 1. Guidance on staffing and workload for histopathology and cytopathology departments, The Royal College of Pathologists.

P102

Diagnostic Challenges of Primary Thalamic Gliomas – Identification of a Minimally Enhancing Neuroradiological Subtype with Aggressive Neuropathology and Poor Clinical Outcome

© K Kurian¹; Y Zhang²; H Haynes¹; M Bradley³

¹Dept of Neuropathology, Frenchay Hospital, Bristol, United Kingdom;

²Dept of Pathology, Bath RUH, Bath, United Kingdom; ³Dept of Neuroradiology, Frenchay Hospital, Bristol, United Kingdom

Aim: To evaluate neuropathology and neuroradiology in the diagnosis and clinical outcome in a cohort of thalamic gliomas.

Methods: Neuropathological and neuroradiological review was undertaken of 25 cases of radiologically suspected thalamic glioma (excl. childhood pilocytic astrocytoma) from 2004-2012 and compared to clinical outcome.

Results: In 48% (12/25) there was a difference in neuropathological and suspected neuroradiological grading of the lesion of one or more grades. In 5/12 (42%) cases the neuroradiology was lower grade than the pathology. In 4/5 (90%) of these cases, we identified a minimally enhancing subtype where the neuroradiology was predicted to be lower grade than neuropathology. In 4/12, (33%) the suspected neuroradiology grade was higher than the final pathology. In 3/4, (75%) of these cases the suspected neuroradiology grade was higher than the neuropathology possibly due to unusual differentiation within the thalamic glioma (central neurocytoma, anaplastic oligodendroglioma, diffuse astrocytoma with piloid features). In 25% (3/12) the biopsy was non-diagnostic.

Neuropathology was a better predictor of clinical outcome than neuroradiology. 9/10 (90%) WHO 4 gliomas and 8/9 (88%) Grade 3 gliomas on neuropathology were dead between 3-7 years after diagnosis. 3/3 (100%) Grade 2 gliomas on neuropathology were alive 3-7 years after diagnosis. 2/3 (67%) of the non-diagnostic cases were alive 3-7 years after biopsy. In 1/3 (33%) of the non-diagnostic cases the outcome was unknown.

Conclusions: Diagnosis of primary thalamic glioma is challenging. This is the first description of a pattern of diffuse infiltration with minimal enhancement on imaging within the thalamus that represents high grade glioma. Neuropathology is overall the best predictor of clinical outcome. Knowledge of the value of neuropathology in predicting clinical outcome may inform a decision to biopsy suspected thalamic gliomas.

P103

Diagnosis of Primary Cerebral Lymphomas

A Shaw¹; V Iyer²; N Rooney³; P Waits³; E Roberts³; H Haynes¹; © K Kurian¹

¹Dept of Neuropathology, Frenchay Hospital, Bristol, United Kingdom;

²Dept of Neurosurgery, Frenchay Hospital, Bristol, United Kingdom; ³Dept of Pathology, BRI, Bristol, United Kingdom

INTRODUCTION: CNS lymphoma can be difficult to diagnose and rebiopsy carries risks and cost. Prebiopsy steroid use is known to affect diagnosis, by reducing the tumour available for biopsy.

METHOD: We examined the rebiopsy rate, steroid use and neuropathological diagnosis of CNS lymphoma over a 10 year period.

RESULTS: We reviewed 102 cases of suspected primary CNS lymphoma over a 10 years, of which 96/102 (94%) were histologically diagnosed and 6/102 (6%) did not achieve a histological diagnosis. 81/96 (84%) were brain lymphoma and 15/96 (16%) spinal lymphoma. 67/81 (82%) were primary brain lymphoma and 14/81 (17%) secondary lymphomas to the brain. In total 78/96 (81%) of the diagnosed CNS lymphoma cases had received steroids prior to biopsy and 18/96 (19%) had not. 9/102 (9%) required rebiopsy and 1/102 (1%) was not rebiopsied despite a non-diagnostic result. 5/9 (56%) rebiopsied cases did not achieve histological diagnosis despite rebiopsy (4 cases had 2 non-diagnostic biopsies, 1 had 3 non-diagnostic biopsies). Of these 2/5 (40%) had received steroids prior to biopsy, 3/5 (60%) had not. 4/9 (44%) cases were diagnostic on rebiopsy and of these 2/4 (50%) had steroids and 2/4 (50%) had no steroids prior to rebiopsy. None of the rebiopsied cases had been sent for PCR analysis of clonality. We sent 7/9 cases which were rebiopsied for clonality assessment by PCR. We found that 3/7 (43%) cases were positive for clonality after PCR. One of these was clonal for a B cell rearrangement and 2 of these were clonal for a T cell rearrangement. The remaining cases had equivocal results or had insufficient DNA from the specimen.

CONCLUSION: The rebiopsy rate in CNS lymphoma at NBT is 9% (lower than the published 12%). In our cohort prebiopsy steroid use does not affect diagnostic yield. We found that PCR for clonality may aid diagnosis in challenging non-diagnostic cases and may help prevent delays in diagnosis and rebiopsy.

P104

IDH Mutation Analysis in Gliomas as a Diagnostic and Prognostic Biomarker

© K Kurian¹; H Haynes¹; C Crosby²; K Hopkins³; M Williams²

¹Dept of Neuropathology, Frenchay Hospital, Bristol, United Kingdom;

²Bristol Genetics Lab, Southmead Hospital, Bristol, United Kingdom;

³Bristol Neuro-Oncology Centre, Bristol, United Kingdom

INTRODUCTION: There is a high rate of IDH1/2 mutations in low and high grade gliomas. IDH analysis of gliomas is a novel method of classification and independent prognostic marker. We compared antibody and sequencing methods for the detection of IDH mutations.

METHOD: 88 samples from 74 patients were identified: 16 WHO Grade 2 gliomas, 30 WHO Grade 3 gliomas and 28 WHO Grade 4 GBM. 31 samples were excluded from genetic analysis due to insufficient sample available for DNA extraction. For immunohistochemistry: sections were stained with anti-IDH1R132H antibody. For sequencing: DNA was extracted from fresh, frozen tissue.

RESULTS: 20/72 cases (28%) were positive for the R132H IDH1 mutation by antibody.

An IDH1 mutation was detected by molecular genetics in 21/57 cases (37%) and no IDH2 mutations were detected (6% expected from previous studies). 5/21 cases (24%) had rare IDH1 mutations not detected by immunohistochemistry (7% expected). Three of these cases displayed the p.Arg132Cys mutation and two displayed p.Arg132Gly.

Where sufficient tissue was available, immunohistochemistry and DNA analysis were fully concordant for the p.Arg132His mutation.

We found a high rate of IDH1 mutations in lower grade lesions (WHO grade II & III) (54%) and a low rate in GBMs (7%). Both grade II gliomas and anaplastic astrocytomas showed a statistically different distribution of IDH1 mutation load compared to GBMs (p<0.0001; p=0.0021 respectively).

CONCLUSION: A rationalised combined approach involving R132H antibody testing and sequencing of negative cases would be ideal for the detection of IDH1 mutations - antibody testing is cheaper than sequencing but sequencing demonstrates rare IDH1 mutations not detected by immunohistochemistry. IDH1 mutation analysis may also have a novel diagnostic role in tumour samples (or biopsies) lacking classical histological features, for example differentiating lower grade tumours and GBM

P105

Histopathology and Clinical Characteristics of Patients undergoing Surgery for Refractory Epilepsy

© A Varghese¹; P Chumas²; J Goodden²; P Goulding¹; A Ismail³

¹Department of Neurology, Leeds Teaching Hospital NHS Trust, Leeds, United Kingdom; ²Department of Neurosurgery, Leeds Teaching Hospital NHS Trust, Leeds, United Kingdom; ³Department of Histopathology, Leeds Teaching Hospital NHS Trust, Leeds, United Kingdom

Background: Mesial Temporal sclerosis (MTS) is the most common neuropathological abnormality in patients undergoing surgery for temporal lobe epilepsy. The aims of this study were to examine the clinical, neurophysiological and imaging features of patients with MTS and to compare outcomes with other morphological tissue diagnoses of patients undergoing surgery for temporal lobe epilepsy. This study was done as part of a service evaluation exercise.

Method: All patients who had surgery for epilepsy from January 2001 to January 2010 were identified from epilepsy surgery database and pathological database. Their notes were reviewed for clinical characteristics and their seizure outcome was classified.

Results: 18 of 34 patients had a pathological diagnosis of MTS [13 females, 5 males]. Of these, 5 patients had co-existing cortical dysplasia. The age of onset of seizures was 1–10 yrs in 56% of patients. The characteristic EEG finding i.e anterior temporal lobe spikes was seen in 15 patients. The characteristic MRI abnormality i.e medial temporal lobe atrophy and high signal was found in all of 18 patients. 78% of these patients were seizure free at 2 years following surgery although only 29% were off medication at this time. Of those who had co-existing dysplasia, 80% were seizure free at 2 years. At 5 years following surgery, 62% of patients were free of seizures of which 38% were off medication.

7 patients had normal histology except for secondary hypoxic or ischaemic changes. Characteristic EEG findings were found in all of cases and MRI abnormality were found in 6 of 7 patients. 57% of these patients were seizure free at 2 yrs. Of 9 tumour patients, 44% were seizure free at 2 years following surgery.

Conclusion: Patients with a tissue diagnosis of MTS appears to have the best outcome following surgery with >75% patients becoming seizure free at 2 years as opposed to about 50% patients with tumour or 'normal histology'.

P106

Myeloid Driven Stem Cell Gene Therapy Corrects the Neuropathology of Lysosomal Disease

© JH McDermott¹; A Sergijenko¹; A Langford-Smith¹; A Liao¹; CE Pickford²; G Nowinski¹; KJ Langford-Smith¹; CLR Merry²; SA Jones³; JE Wraith³; RF Wynn⁴; FW Wilkinson¹; BW Bigger¹

¹Stem Cells & Neurotherapies, University of Manchester, Manchester, United Kingdom; ²Stem Cell Glycobiology, University of Manchester, Manchester, United Kingdom; ³Genetic Medicine, St Mary's Hospital, Manchester, United Kingdom; ⁴Blood and Marrow Transplant Unit, RMCH, Manchester, United Kingdom

Mucopolysaccharidosis IIIA (MPS IIIA) is an inherited lysosomal storage disorder resulting from a mutation in the gene coding for N-sulfoglucosaminase sulfohydrolase (SGSH), an enzyme involved in the degradation of heparan sulphate (HS). The disease is characterised by progressive loss of cognitive and motor functions which present during early childhood. Enzyme replacement therapy is feasible in this disease but fails due to the presence of the blood brain barrier. Haematopoietic Stem Cell Transplant (HSCT) circumvents this by trafficking of donor derived monocytes to the brain and engraftment as microglia, however cells produce insufficient enzyme for cross-correction. We have previously used a lentiviral vector to overexpress SGSH in WT HSCT, demonstrating neuropathological correction, however, lentiviral SGSH expression in autologous MPS IIIA HSCs is not sufficient, therefore reducing the clinical relevance of these findings. To improve expression and specificity, codon-optimised SGSH lentiviral vector constructs under the myeloid specific CD11b (LV-CD11b-SGSH) or ubiquitous PGK promoter (LV-PGK-SGSH) were developed and used to transduce MPS IIIA HSCs. The transduced HSCs were then transplanted into MPS IIIA mice.

At 8 months, LV-PGK-SGSH provided some improvement in neuropathology, achieving correction of GM2 ganglioside storage and pre-synaptic vesicles within the cortex. However, on analysis of brain enzyme activity, LV-CD11b-SGSH increased SGSH to 11% of WT activity manifesting significantly higher levels than the 7% achieved by LV-PGK-SGSH. LV-CD11b-SGSH fully corrected neuroinflammation, lysosomal swelling and HS accumulation within the cortex and amygdala.

Therefore we would suggest that the LV-CD11b-SGSH vector should be the vector of choice when pursuing the treatment of MPS IIIA through transplant of transduced MPS IIIA HSCs.

P107

Locally Aggressive Fibrous Dysplasia

TG Kashima¹; NG Gamage¹; H Ye²; FM Amary²; AM Flanagan²; H Giele³; S Ostlere¹; J Reynolds¹; © NA Athanasou⁴

¹Nuffield Orthopaedic Centre, Oxford, United Kingdom; ²Royal National Orthopaedic Hospital, London, United Kingdom; ³Nuffield Orthopaedic Centre, London, United Kingdom; ⁴Nuffield Department of Orthopaedics, Rheumatology and Musculoskeletal Sciences, Nuffield Orthopaedic Centre, University of Oxford, Oxford, United Kingdom

Fibrous dysplasia (FD) is a benign fibroosseous lesion which is usually confined to bone. There are rare reports of locally aggressive fibrous dysplasia. In this study we document clinical, radiological and pathological findings in five cases of locally aggressive fibrous dysplasia, mainly involving the ribs. Lesions in these cases have been followed up for 5–23 years. Two of the cases recurred. The lesions showed typical histological features of fibrous dysplasia with irregular woven bone trabeculae separated by a cellular fibrous stroma but not lined by plump osteoblasts; however, unlike typical FD, these lesions had extended through the bone cortex into surrounding soft tissue (and in one case into adjacent vertebral bone). The lesions were negative for CDK4. Two of the cases had a GNAS mutation. Our findings indicate that FD can rarely be locally aggressive with extension into surrounding soft tissues and that these lesions can be distinguished from low-grade intramedullary osteosarcoma by lack of expression of CDK4 and the presence of a GNAS mutation.

P108

Employing MDM2 Amplification to Assess the Clinical Outcome in 92 Patients with Peripherally-Sited Atypical Lipomatous Tumours

© GE Forbes¹; R Tirabosco¹; MF Amary¹; AM Flanagan²

¹The Royal National Orthopaedic Hospital, Middlesex, United Kingdom; ²UCL Cancer Institute, London, United Kingdom

Atypical lipomatous tumours (ALT) account for approximately 45% of all liposarcomas representing the largest subgroup of aggressive adipocytic neoplasms. At surgically amenable peripheral sites, wide excision should be curative. However, the risk of local recurrence is reported to range from 3 to 63%. In addition, a risk of dedifferentiation on recurrence is reported as 6%. The literature shows that there is a greater risk of diagnosing large lipomas as ALT than diagnosing ALT as lipomas. Hence the recent report that MDM2 amplification is 100% specific and 93.5% sensitive for diagnosing ALT makes this marker a valuable adjunct in making a correct diagnosis.

Aim: To use MDM2 as a marker for ALT to determine the a) incidence of local recurrence of ALT, and b) incidence of dedifferentiation of peripherally-sited ALT in patients followed for at least 4 years.

Methods: Retrospective review of the pathology and electronic files of patient data within the histopathology department between 2002 and 2008.

Results: ALT recurred at least once in 31 (32.0%) of 97 patients. Of the 97, 21 (21.6%) ALT presented de novo with a dedifferentiated component and 4 of these recurred. Of 18 ALT that recurred once one became dedifferentiated. Six ALT recurred twice, of which 3 tumours became dedifferentiated. Two recurred 3 times, one of which became dedifferentiated.

Two patients developed metastatic disease, both from dedifferentiated liposarcomas. The period to first recurrence/residual disease ranged from <12–240 months; mean = 62.8 months. When initial surgery was performed at a specialist centre, the incidence of recurrence was 19.5%. When surgery was performed elsewhere, recurrence occurred in 80.0% of cases.

Conclusion: Previously reported local recurrence rates of ALT are notoriously variable. Molecular markers improve the accuracy of diagnosing mature lipomatous tumours and therefore help to accurately classify tumours to monitor their true progression and outcome. The data imply that patients with ALT benefit from being treated in specialist units, resulting in a significantly smaller risk of recurrence.

P109

This abstract has been withdrawn.

P110

The Rate of Malignant Skin Tumours in Renal Transplant Recipients in SW London and Brighton

© C Roche¹; J Dobson¹; M Quante²; J Chow¹

¹St George's, University of London, London, United Kingdom; ²Royal Sussex County Hospital, Brighton, United Kingdom

Purpose: To assess the rate of malignant skin tumours in immunosuppressed renal transplant recipients in London & Brighton.

Background: Transplant recipients require immunosuppressive therapy to prevent graft rejection which conveys an increased risk of malignancy, mostly skin tumours. For kidney recipients the rate of skin tumours at 10yrs followup ranges from 10-40% depending on UV light exposure. In the UK, the mean annual incidence after transplant has been reported at 11%. The rate of squamous cell carcinoma is particularly increased. National guidelines were introduced to improve outcomes for skin cancer in 2006 and there is a need for recent data and data for South-East England.

Methods: The pathology records were reviewed for 712 immunosuppressed patients who received a kidney transplant at our hospital between 1995-2008. Details of all skin tumours were recorded and analysed.

Results: Mean length of followup was 9yrs. 56 (7.9%) of 712 patients developed ≥ 1 skin tumour. 43 (9.4%) males and 13 (5.1%) females developed a tumour, OR 1.9 ($p = 0.04$). 211 tumours were found, of which 48.8% were squamous cell carcinomas, 48.3% were basal cell carcinomas and 2.8% were malignant melanomas. The rate of SCC was estimated at 33 times that of the local population. The mean time to first tumour was 5.5yrs. The mean no. of tumours per patient was 4 with a mean interval of 9 months between tumours.

Conclusions: Kidney transplant recipients in this region appear to have a lower risk of skin tumours than expected from the literature, though it remains significant at 8%. As expected, the BCC:SCC ratio was narrowed (1:1) compared to the normal population (7:1), reflecting the particular risk of the more dangerous SCC. Our findings add to the body of evidence which is increasingly important as more transplants are done and patients immunosuppressed.

This study was made possible by a Pathsoc bursary, gratefully received.

P111

A Statistical Framework for Analysing Hypothesised Interactions Between Cells Imaged using Multispectral Microscopy and Multiple Immunohistochemical Markers

C Rose¹; K Naidoo²; V Clay³; K Linton¹; J Radford¹; © RJ Byers¹

¹The University of Manchester, Manchester, United Kingdom; ²St Thomas's Hospital, London, United Kingdom; ³Wythenshawe Hospital, Manchester, United Kingdom

Histopathological diagnosis and prognostication relies on morphological pattern recognition and interpretation but as the number of biomarkers that can be measured in tissue increases the ability for human prognostic pattern recognition with multiple markers decreases. To overcome this we have developed an automated method for characterizing and visualizing the statistical distribution of hypothesized interactions / pairwise spatial relationships between cells with particular immunohistochemical characteristics. Follicular lymphoma was used as a model system, 26 samples stained by IHC for CD20 and YY1, a prognostic marker, and images captured using a Nuance multispectral imager from which the x,y co-ordinates of single +ve, double +ve or double -ve cells were obtained, and cells assigned to classes accordingly. The statistical distribution of the frequency of occurrence of pairs of cells (of each combination of classes) within a pre-specified distance of one another was estimated for each sample. Distributions were summarised for each patient using measures of distribution peakiness (energy and entropy). A Kaplan-Meier leave-one-out analysis showed that patients whose distributions had high entropy had significantly shorter survival (7.70 vs 110 months, $P=0.00750$). The results demonstrate the ability to identify prognostic patterns without a priori knowledge and whilst just two markers were evaluated in the present example the method is capable of scaling to any number of marker, with potential for automated identification of diagnostic and prognostic patterns of cellular interaction, facilitating interpretation of higher order multiplex staining experiments.

P112

MALDI Imaging Mass Spectrometry for Tissue Proteomics in Gastric Cancer

© BD Balluff¹; A Walch²; LA McDonnell¹

¹Leiden University Medical Center, Leiden, Netherlands; ²Helmholtz Zentrum Muenchen, Munich, Germany

Matrix-assisted laser desorption/ionization (MALDI) imaging mass spectrometry is gaining increasing interest as a new analytical technique in molecular pathology, as it allows the unlabeled *in situ* measurement of hundreds of molecules (such as proteins) within the histomorphological context of tissue sections. Complex molecular patterns can be obtained for specific histological entities, such as tumour cells or inflammatory cells, without destroying the natural morphology of the tissue sections.

In our studies, we use MALDI imaging mass spectrometry for the identification of clinically relevant proteins in terms of prognosis and therapy response in gastric cancer patients. Our results highlight the usefulness of MALDI imaging for providing novel and clinical relevant information from tumour tissues, as well as its potential for tissue diagnostics.

P113

Phenotyping of Tumour-Infiltrating Lymphocytes in Melanoma Using Tissue Cytometry

JR Mansfield¹; © RC Lloyd²; K Lane¹; CM van der Loos³; CC Hoyt¹

¹PerkinElmer, Waltham, United States; ²PerkinElmer, Seer Green, United Kingdom; ³Amsterdam Medical Centre, Amsterdam, Netherlands

In many cancers, tumour-infiltrating lymphocytes (TILs) indicate levels of tumour immunogenicity and are a strong predictor of survival. An understanding of the phenotype and spatial distribution of TILs within tumour regions would be advantageous for characterizing host response. However, visual TIL assessment is prone to error and multi-marker quantitation is difficult with standard methods. Here we present a multi-marker, computer-aided event-counting method for the determining the phenotypes of lymphocytes in melanoma sections using a novel multispectral imaging (MSI) approach. A section of a tissue microarray containing 120 melanoma cores was stained for CD3, S100, Foxp3 and haematoxylin. This was imaged using MSI and the individual staining of each marker separated from each other using spectral un-mixing. The images were analysed using software which had been trained to recognize the tumour area based on the S100 staining pattern. Then the Foxp3 status of each CD3+ TIL was then determined. Results indicate that machine-learning software can be trained to accurately recognize tumour regions within each core. MSI enabled the accurate quantitation of three immunostains in the sample without crosstalk. Within the tumour region of each core it was possible to count the CD3+ TILs and then determine the Foxp3 status of each. This multi-marker phenotyping and counting approach shows the potential for broad applicability in the assessment of TILs in many solid tumours.

Abstract Reviewers

Dr EW Benbow, Manchester
Dr JLG Blaauwgeers, Amsterdam
Dr WAM Blokk, Nijmegen
Dr JVMG Bovée, Leiden
Dr RJ Byers, Manchester
Dr RR de Krijger, Delft
Prof AJ Freemont, Manchester
Prof KC Gatter, Oxford
Prof R Goldschmeding, Utrecht
Prof JR Gosney, Liverpool
Dr T Helliwell, Liverpool
Prof H Hollema, Groningen
Dr N Kirkham, Newcastle
Dr RD Liebmann, Kent
Prof J Lowe, Nottingham
Prof WG McCluggage, Belfast
Prof RFT McMahon, Manchester
Prof AM McNicol, Brisbane
Prof GA Meijer, Amsterdam
Prof GI Murray, Aberdeen
Dr PGJ Nikkels, Utrecht
Prof GJA Offerhaus, Utrecht
Dr P Ramani, Bristol
Prof ISD Roberts, Oxford
Prof PJ Slootweg, Nijmegen
Prof JG van den Tweel, Utrecht
Prof PJ van Diest, Utrecht
Prof FJ van Kemenade, Amsterdam
Dr C Verrill, Oxford
Dr A Vink, Utrecht
Prof P Wesseling, St Radboud
Dr KP West, Leicester
Dr BS Wilkins, London
Dr SM Willems, Utrecht

Presenter's Index

A		G		O	
Acres, MJ.....	P36	Gafà, R.....	P71	Olaofe, OO.....	P66
Ahmad, O.....	P31	Gay, LJ.....	P26	P	
Ahmed, BLR.....	P38, P44	Geurts-Giele, WRR.....	P33	Pettinger, KJ.....	P64
Akpobi, KC.....	P52	Going, JJ.....	P54, P55	Platt, C.....	P99
Alchami, F.....	P40, P47, P82, P101	Goos, JA.....	P67	R	
Aleskandarany, MA.....	P4, P5, P84	Gopinath, PP.....	P10	Ramsay, AD.....	P95
Alexe, DM.....	P1	H		Reis-Filho, JS.....	S2
Al Ghamdi, S.....	P30	Heath, JJ.....	P37	Roche, C.....	P110
Alrahbi, N.....	P96	Heatley, N.....	P45	Ryan, C.....	P46
Amor, S.....	P100	Hiemstra, AC.....	P76	S	
Anjorin, A.....	P2	Hoefnagel, LDC.....	P13	Sarper, M.....	P19
Appukutty, SJ.....	P49, P50	Hubers, AJ.....	P20	Sergi, C.....	P78
Armstrong, RHM.....	P98	Hughes, TA.....	PL4	Sergi, CS.....	P79
Athanasou, NA.....	P107	Huibers, MMH.....	P24, P25	Shaban, MIH.....	P83
Azam, AS.....	P15, P43, P62	J		Shepherd, NA.....	S8
Aziz, AK.....	P73	Jackson, M.....	P58	Sie, D.....	PL6
B		Jones, C.....	PL7	Speel, EJM.....	P48, PL3
Balluff, BD.....	P112	K		Speller, AVM.....	P17
Bernards, R.....	S10	King, JB.....	P75	Steenbergen, RDM.....	P87
Bijron, JG.....	P88	Knijn, N.....	P74	Sundaresan, V.....	P6, P7
Blits, M.....	P34, P35	Korkmaz, HI.....	P3	Sutton, KM.....	P32
Blokx, WAM.....	S11	Kozyar, O.....	P85	T	
Booth, ME.....	P8	Krijgsman, O.....	P94	ter Horst, EN.....	P22
Bosman, FT.....	S9	Kurian, K.....	P102, P103, P104	Tlsty, TD.....	S1
Bovenschen, N.....	P27, P29	Kurian, RR.....	P51	U	
Brolly, J.....	P65	L		Uijterwaal, MH.....	PL1
Byers, RJ.....	P93, P111	Lacle, MM.....	P11	V	
C		Lawes, KP.....	P91	van den Broek, E.....	P68
Carvalho, B.....	P72	Lee, AHS.....	S3	Varghese, A.....	P105
Clevers, JC.....	S12	Lloyd, RC.....	P113	Vargiamidou, A.....	P14
D		Lok, SI.....	P23	Verhoef, VMJ.....	P89
de Cuba, EMV.....	P59	M		Verma, R.....	P9
de Groen, FLM.....	P70	Maurice, Y.....	P16	Vos, S.....	P18
de Groot, JS.....	P12	McCarthy, H.....	P90	Vreuls, CPH.....	P81
de Leng, WWJ.....	P56, P57	McDermott, JH.....	P106	W	
de Wit, M.....	P69	Meijer, GA.....	S7	Wright, NA.....	P53, PL5, S6
Derksen, PWB.....	S4	Mifsud, W.....	P77	Z	
Diosdado, B.....	P28	Moore, L.....	P42, P92	Zakarneh, L.....	P86, P97
Du, MQ.....	S5	Murphy, HE.....	P39		
F		N			
Fadhil, WM.....	P60, P61	Naaijken, BA.....	P21		
Fateen, W.....	P41, P80	Nicholls, JD.....	P63		
Flanagan, AM.....	PL8	Niedobitek, G.....	PL2		
Forbes, GE.....	P108				